

Mapping of Broca's Area and the Primary Motor Cortex for Laryngeal Muscles Under General Anesthesia – A Review of 4 Cases

James Watt, BS, CNIM

Kent Rice, MS, REPT, CNIM DABNM

Ruthanne Leo, BS, CNIM

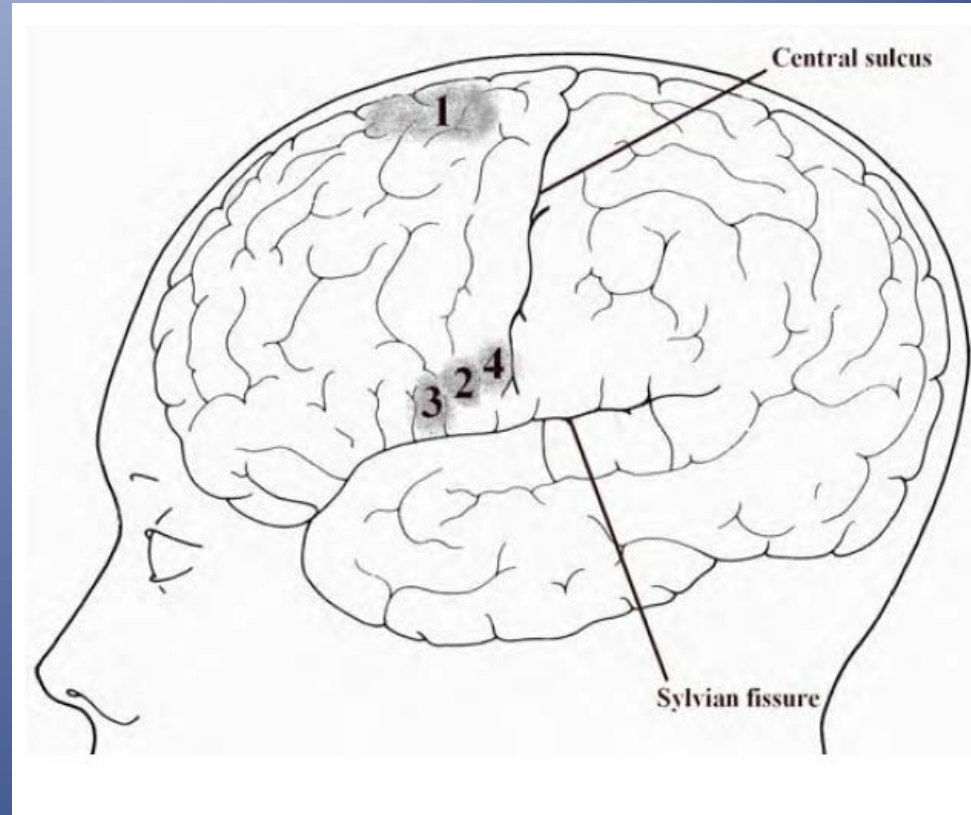
Sandeep Mital, MD, F.R.C.S.C

Traditional Broca's Mapping

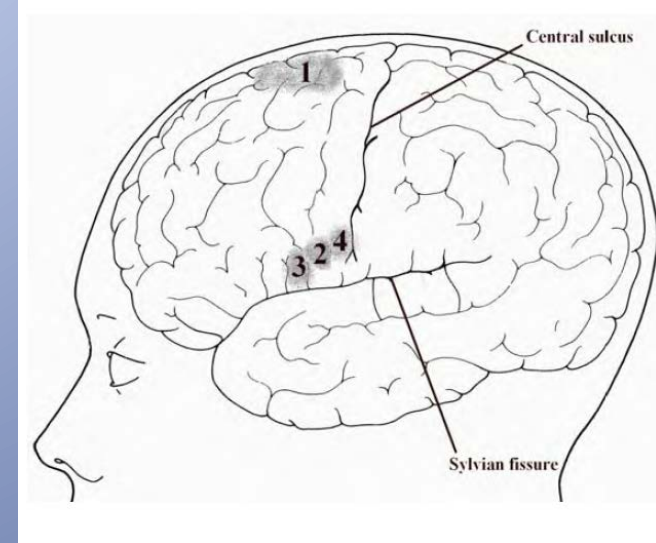
- Penfield Stimulus Technique
 - 50-60 Hz, 1 mS, 1-4 seconds applied trains
 - Extraoperative awake mapping through implanted grids
 - Intraoperative mapping using bipolar Ojemann probe in awake patient
- Broca's area identified by eliciting speech arrest in the patient during stimulation

Anatomy

- (4) Primary motor cortex for oro-pharyngeal-laryngeal muscles
- (2) Primary negative motor speech area
- (1) Supplementary negative motor area
- (3) Broca area – posterior part of the inferior frontal gyrus

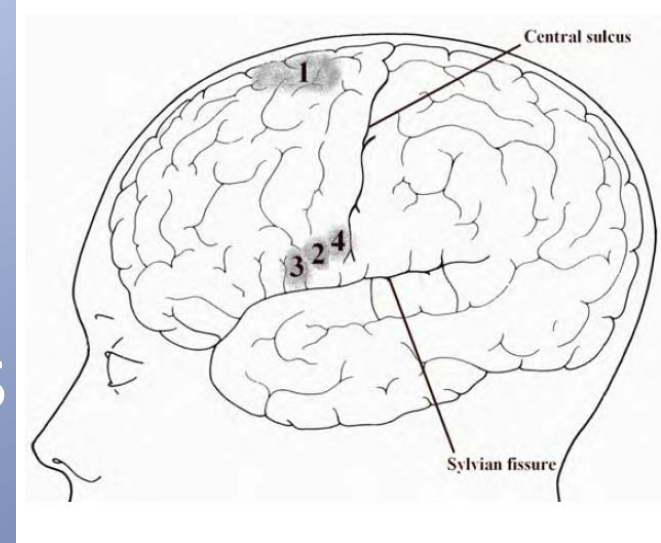


Speech arrest during a counting task – Clinical features



- Broca area (3); Speech arrest **without simultaneous motor responses in oro-pharyngeal-laryngeal** muscle group. During speech arrest the subject is **able to execute voluntary tongue movement (i.e. wiggling from side to side)**.
- Negative motor areas (1,2); Speech arrest **without simultaneous motor responses in oro-pharyngeal-laryngeal** muscle group. During speech arrest the subject is **not able to execute voluntary tongue movement (i.e. wiggling from side to side)**.
- Primary motor cortex (M1) for oro-pharyngeal-laryngeal muscles; Speech arrest **with simultaneous** motor response in oro-pharyngeal-laryngeal muscle group. During speech arrest the subject is **not able to execute voluntary tongue movement (i.e. wiggling from side to side)**.

Speech arrest during a counting task – Neurophysiologic features



- Broca area; Speech arrest with presence of long latency response in laryngeal muscles (Deletis et al., 2008)
- Negative motor areas; Speech arrest with electrical silence in laryngeal muscles
- Primary motor cortex (M1) for oro-pharyngeal-laryngeal muscles; Speech arrest with a short latency response in laryngeal muscles (Amassian et al., 1987; Ertekin et al., 2001; Rödel et al., 2004; Deletis et al., 2009).

New neurophysiologic marker for Broca's area and methodology for identifying Broca's under general anesthesia

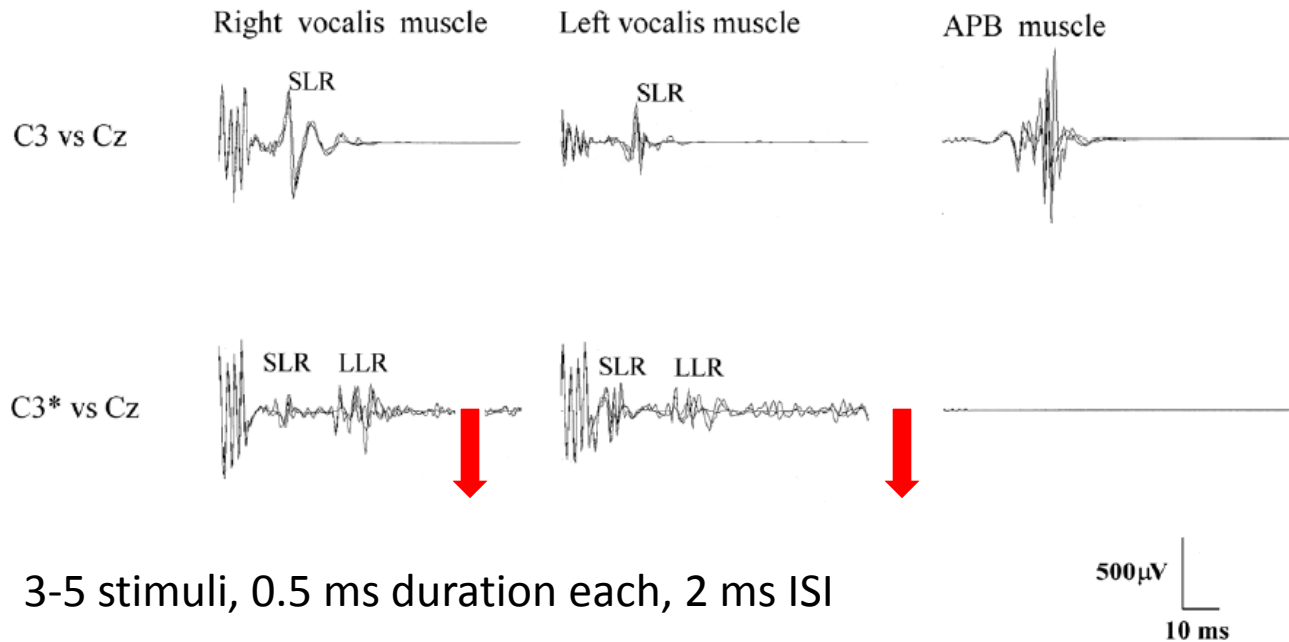
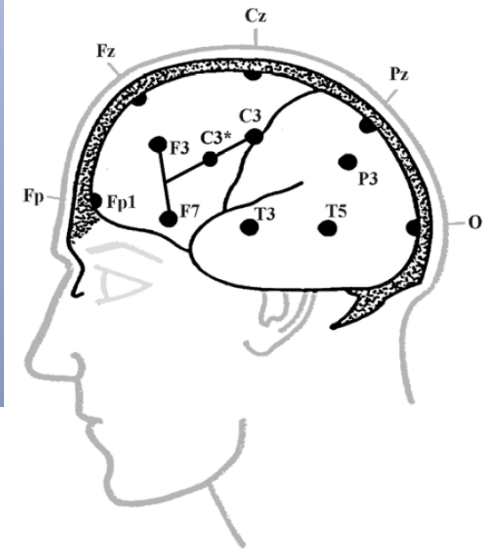
- Deletis demonstrated that stimulation of Broca's area versus primary motor cortex for oro-pharyngeal-laryngeal muscles produced distinct responses from the vocalis muscles.

Responses elicited in the vocalis muscles after electrical stimulation of motor speech areas

V. DELETIS, S. ULKATAN, B. CIONI*, M. MEGLIO*, G. COLICCHIO*,
V. AMASSIAN**, R. SHRIVASTAVA

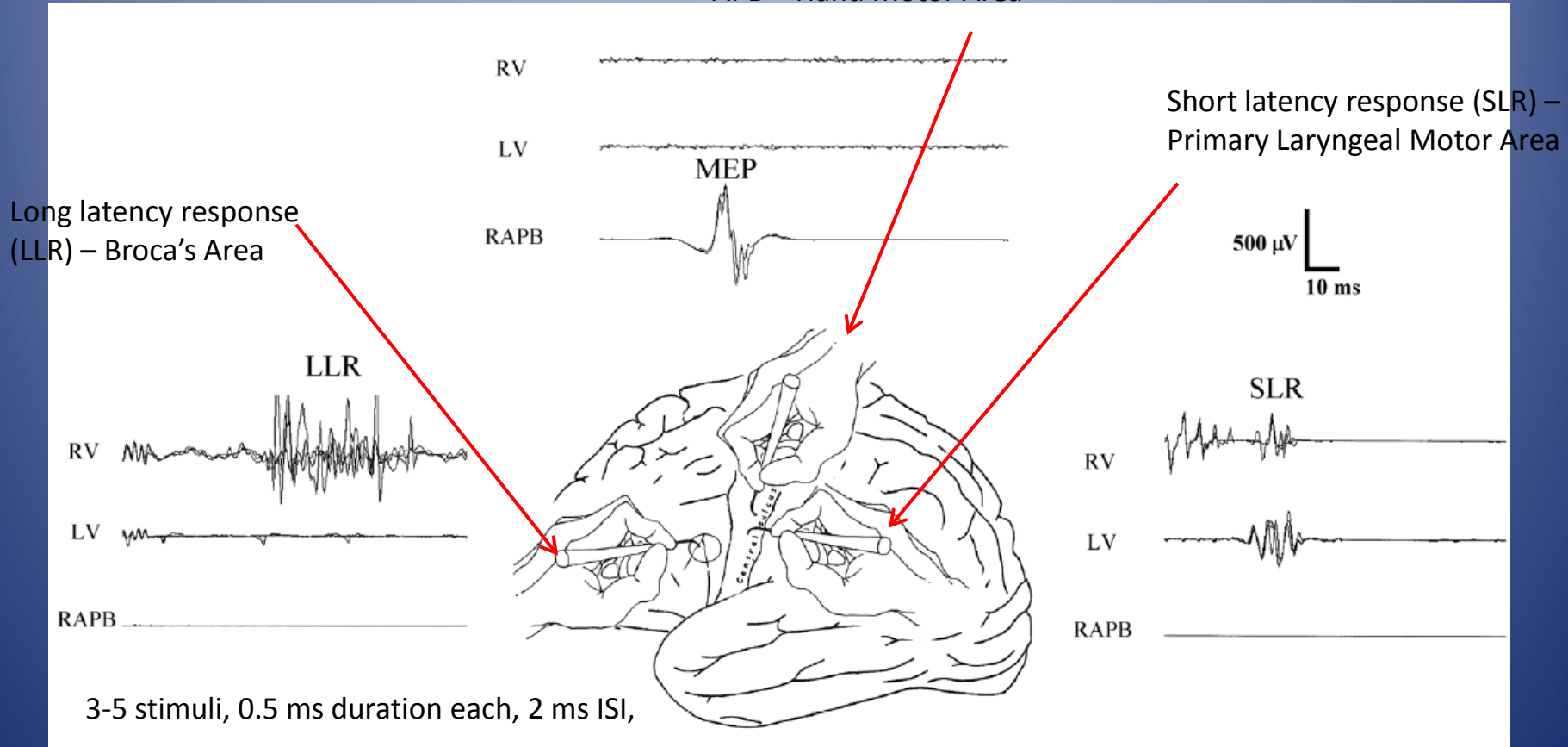
Deletis, V., Ulkatan, S., Cioni, B., Meglio, M., Colicchio, G., Amassian, V., Shrivastava, R. (2008). Responses elicited in the vocalis muscles after electrical stimulation of motor speech areas. *Rivista Medica*. 14:159-165.

Transcranial stimulation at C3 vs C3*



Three distinct responses identified

APB – Hand Motor Area

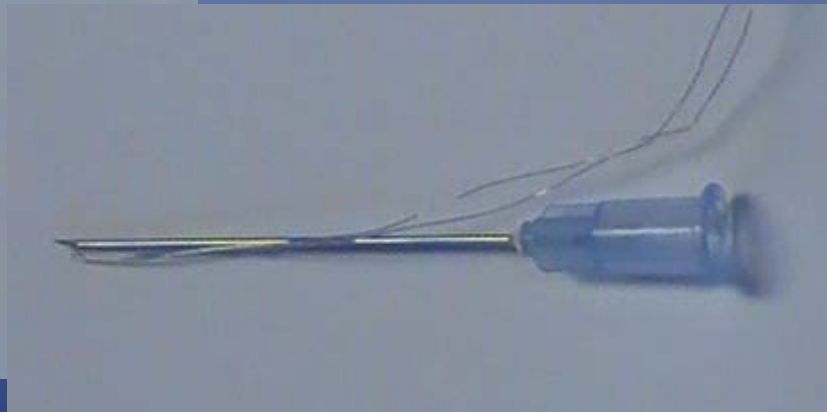


SLR and LLR elicited by TES and DCS had similar latency; SLR had latency of 10-12 ms while LLR had latency of 35-50 ms and their amplitude was higher when elicited by DCS than by TES. SLR was well synchronized, and short duration, while LLR was desynchronized and of the long duration.

Recording from Vocalis Muscle

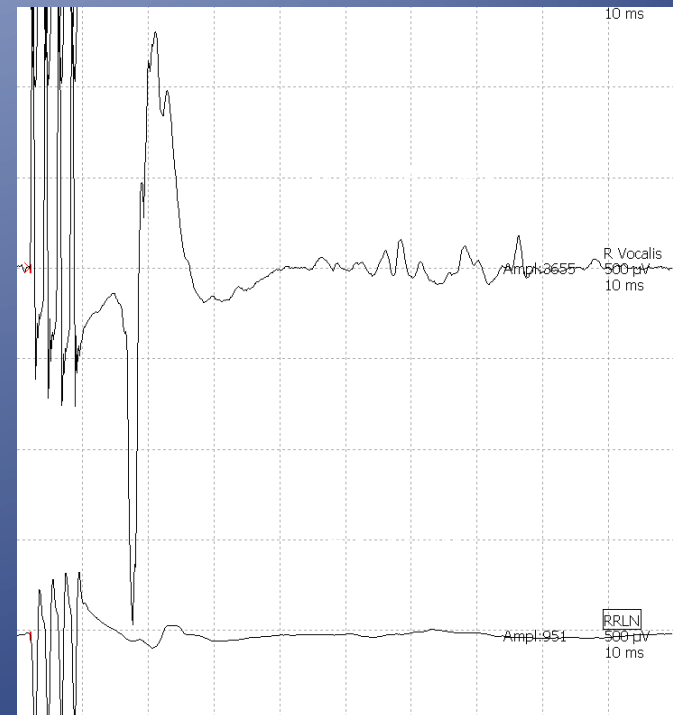


- Two insulated hook wire electrodes were placed
 - 76 μm in diameter passing through 27 gauge needles (hook wire electrode, specially modified, Viasys Healthcare WI, MA).
 - Impedances of electrodes were around 20 K Ohm.



Why use hookwires instead of endotracheal tube electrodes?

- Hookwire response amplitudes are larger by an order of magnitude (Bigelow 2002)
- Closely spaced bipolar hookwires are less susceptible to far-field contamination from adjacent neck muscles



Anesthesia

- TIVA with Propofol (100-150 $\mu\text{g}/\text{kg}/\text{min}$) and Fentanyl (1-1.5 $\mu\text{g}/\text{kg}/\text{hour}$).
- A short-acting muscle relaxant (Rocuronium 50 mg/kg) was administered for intubation purposes only.
- No local anesthetic utilized in throat
- The anesthesia regimen, blood pressure and temperature were kept constant throughout the procedures.
- Recovery from muscle relaxation was monitored by the train-of-four technique and recorded from the APB muscle after stimulation of the median nerve at the wrist.

Is TIVA necessary?

- Yes!
- At least one synapse between Broca's and Primary motor
 - we are essentially activating the Broca's response via I-waves rather than D-waves!
- I-waves are quite sensitive to anesthesia, although they can be facilitated by a stimulus train

Primary motor vs Broca's

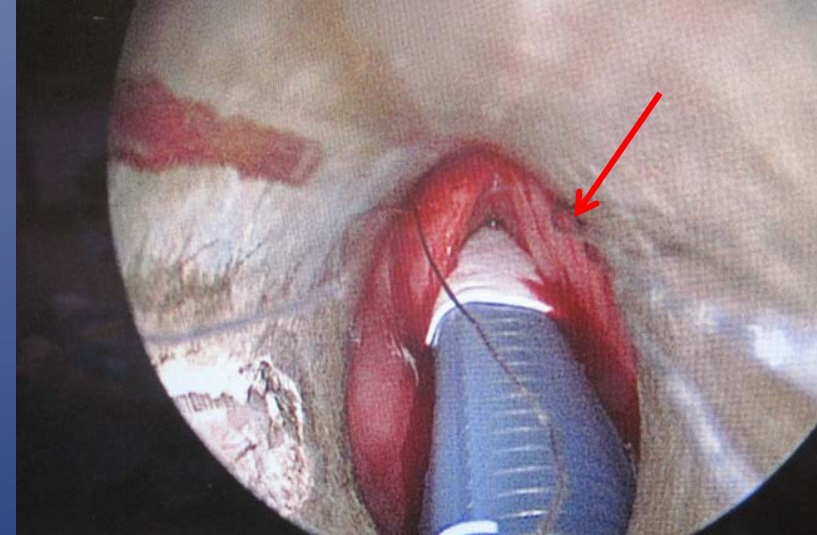
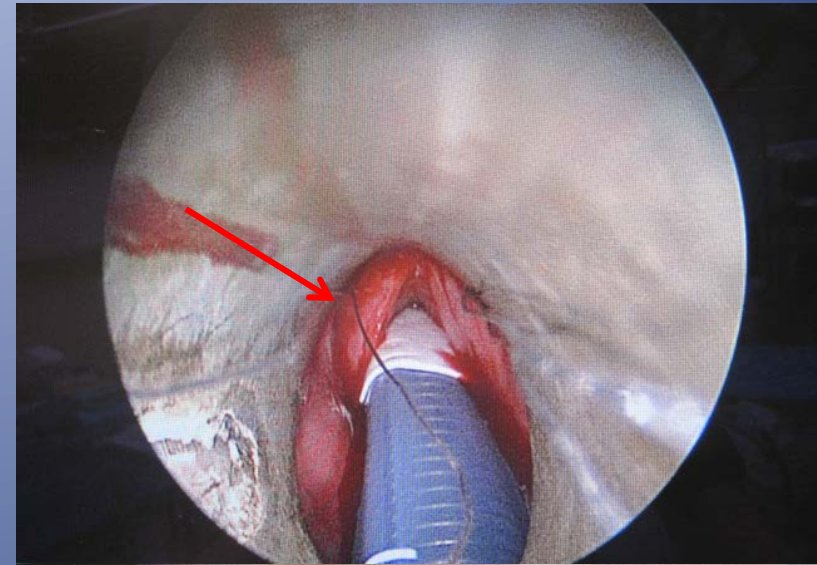
- Stimulation of the lateral part of precentral gyrus, lateral to the cortex eliciting response in contra lateral APB muscle, elicits SLR in bilateral vocalis muscles
 - This corresponds to the area of primary motor cortex for the oropharyngeal muscles
- Stimulation of a very restricted region of the posterior lower frontal gyrus (10mm x 10mm) elicit only LLR in either the ipsilateral or contralateral vocalis muscle

Patient 1

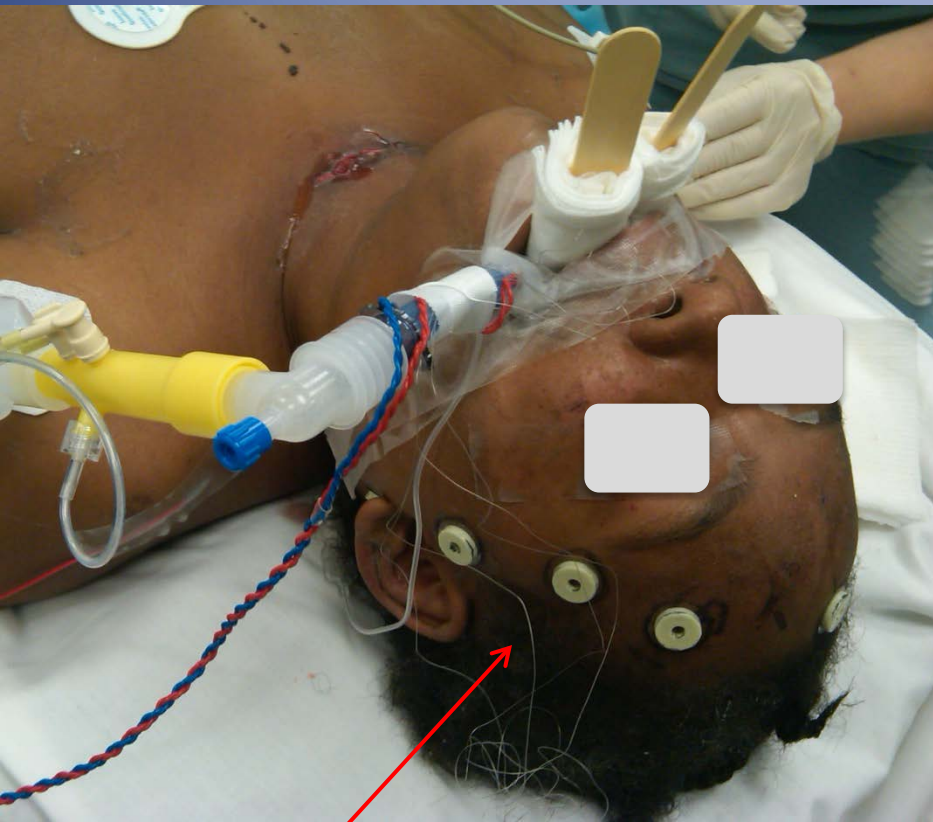
- Female, 40 yrs old
- EEG indicates status
- Patient unresponsive for nearly 2 weeks
- No pharmacological relief
- Speech and motor function could not be assessed prior to procedure

Recording from Vocalis Muscle

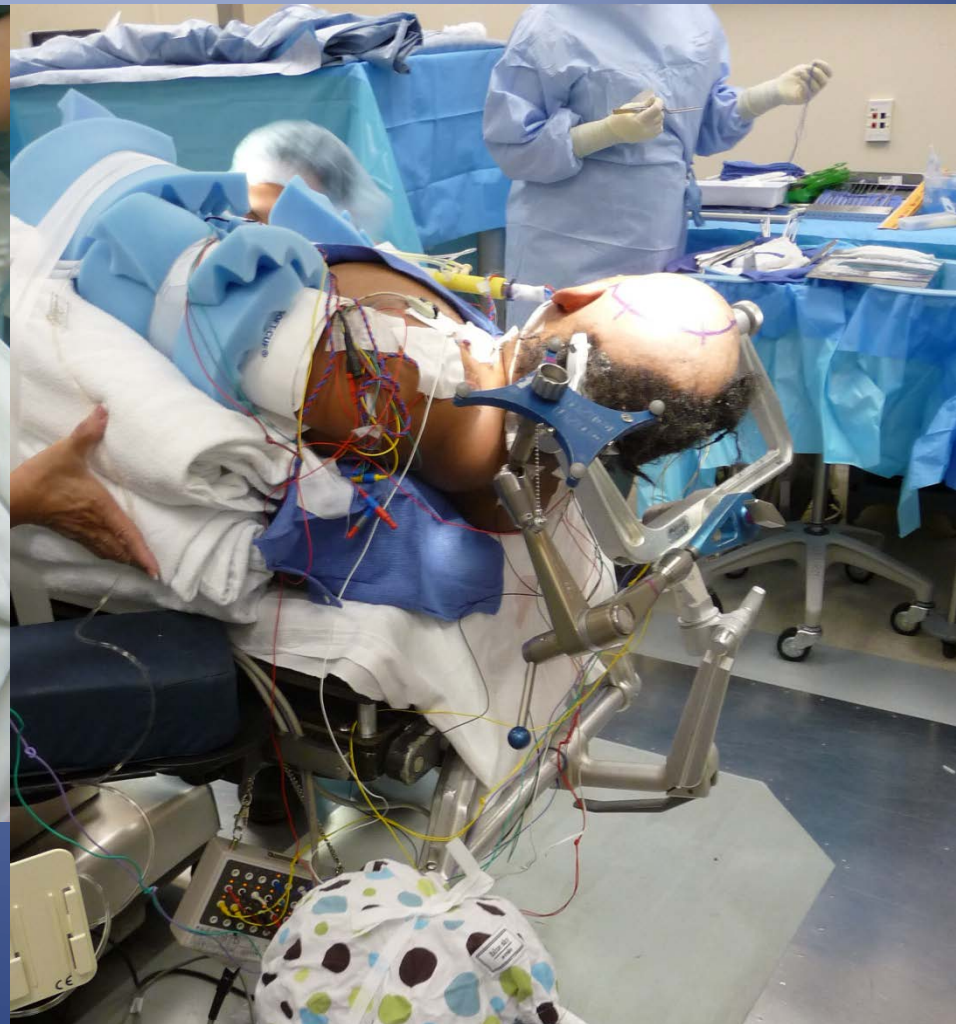- Following intubation, two electrodes inserted into each vocalis muscle by and ENT using a rigid laryngoscope.



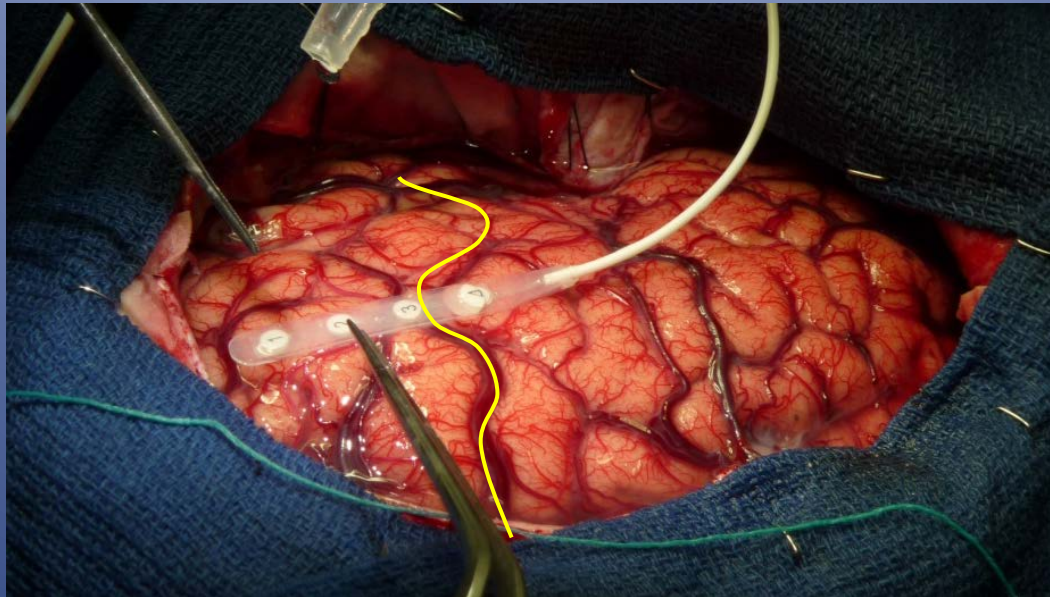
Bite blocks are placed, and the patient is positioned in the Mayfield



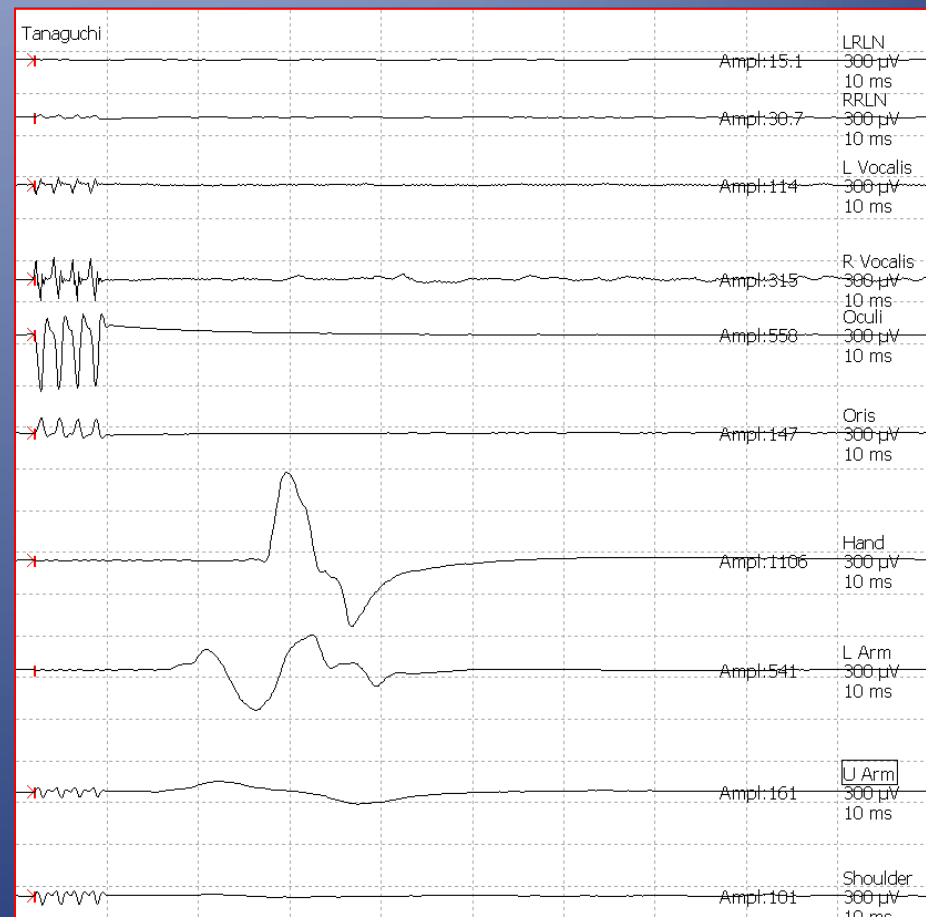
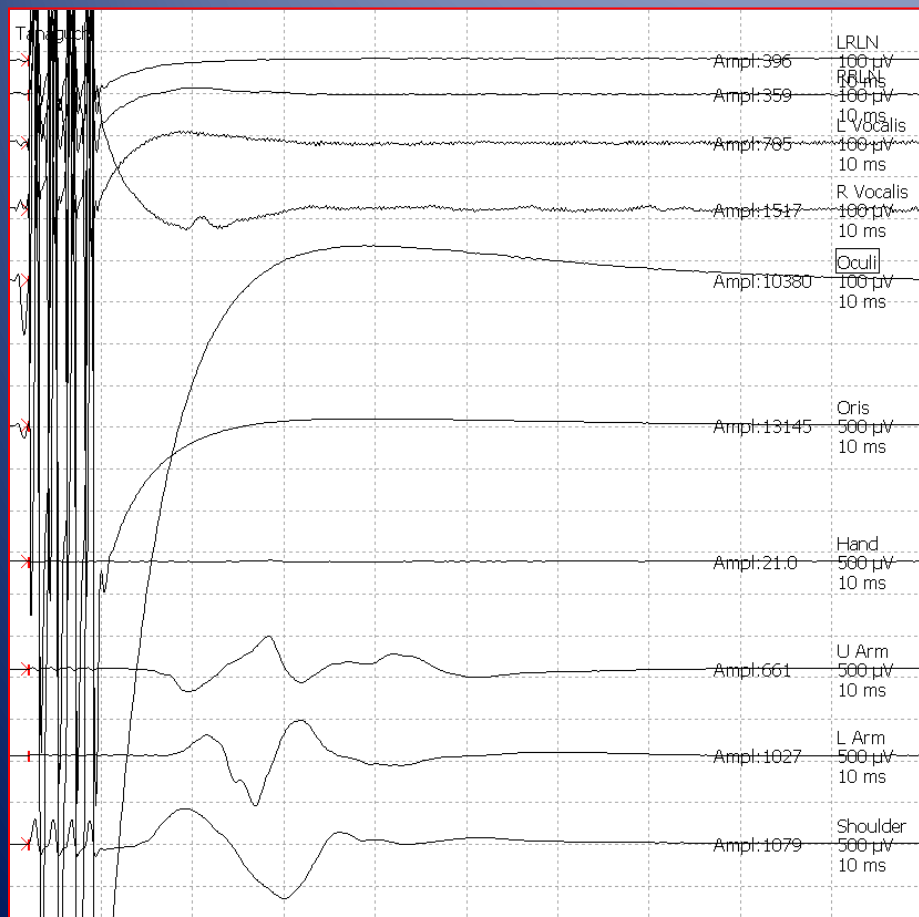
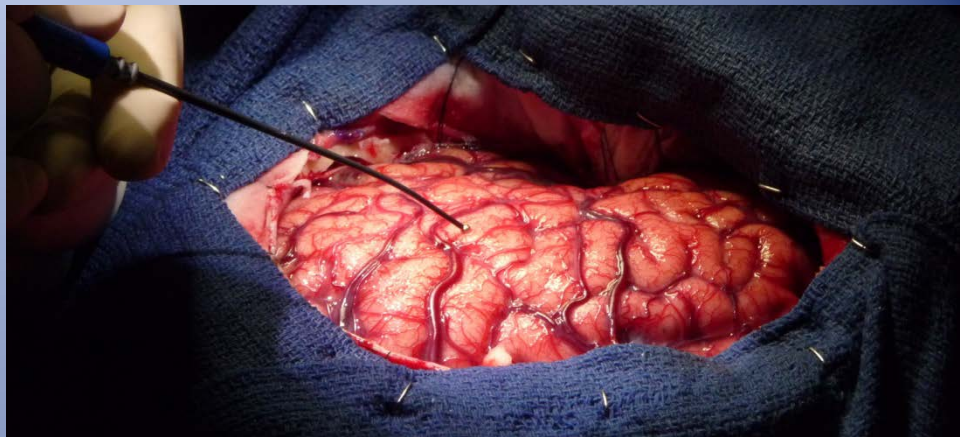
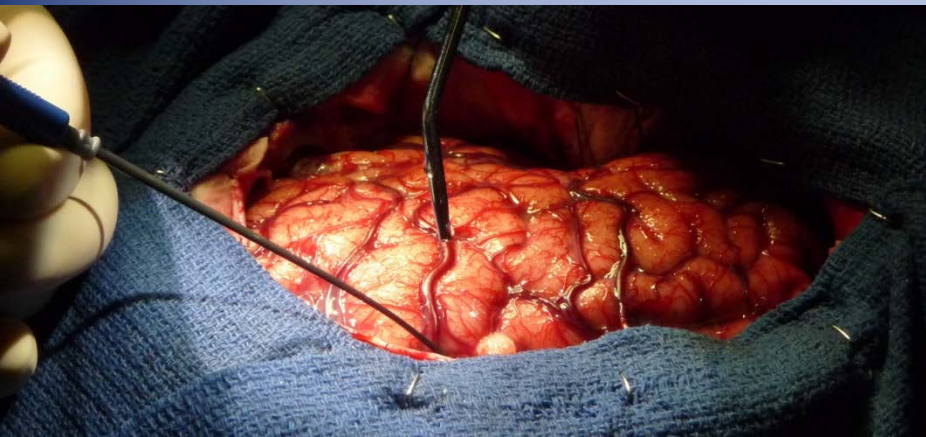
Hookwire strands twisted and secured

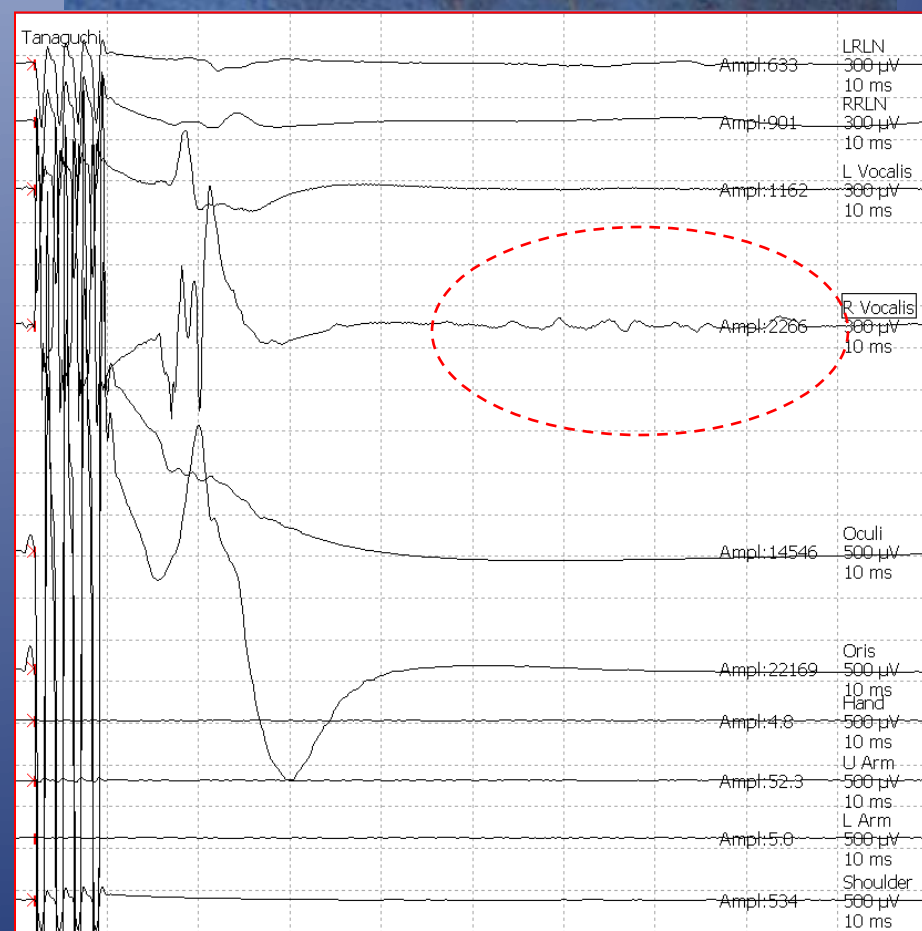
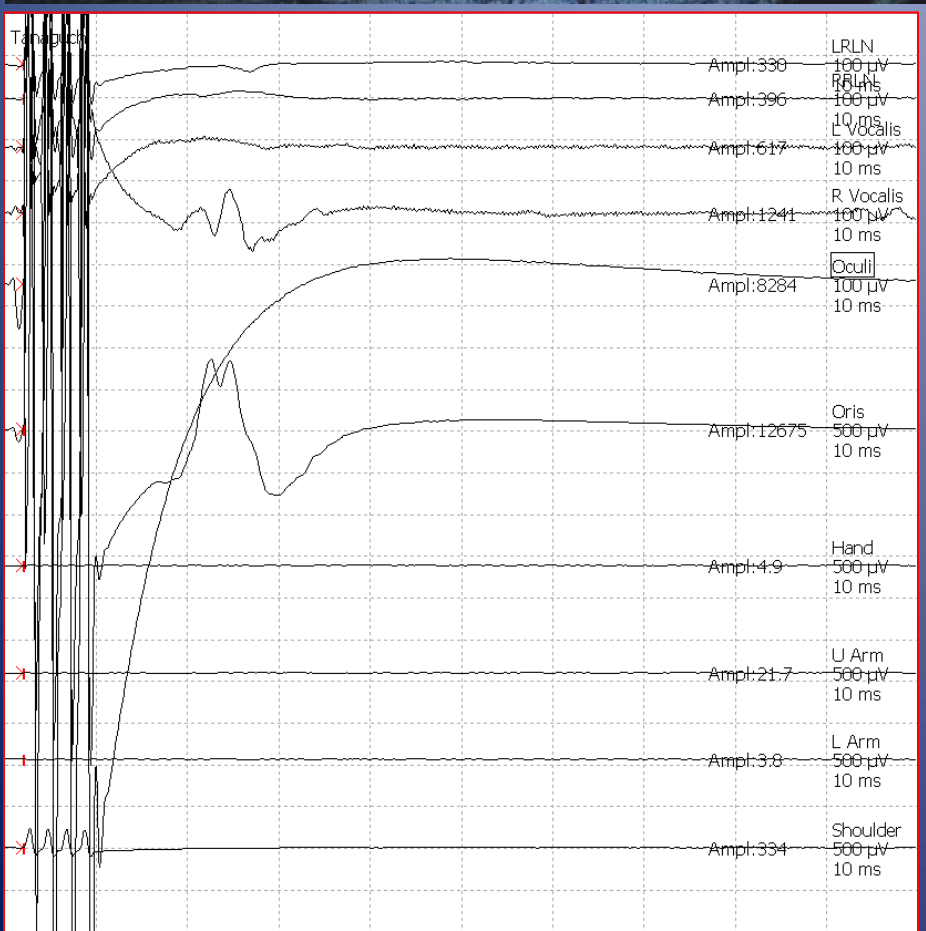
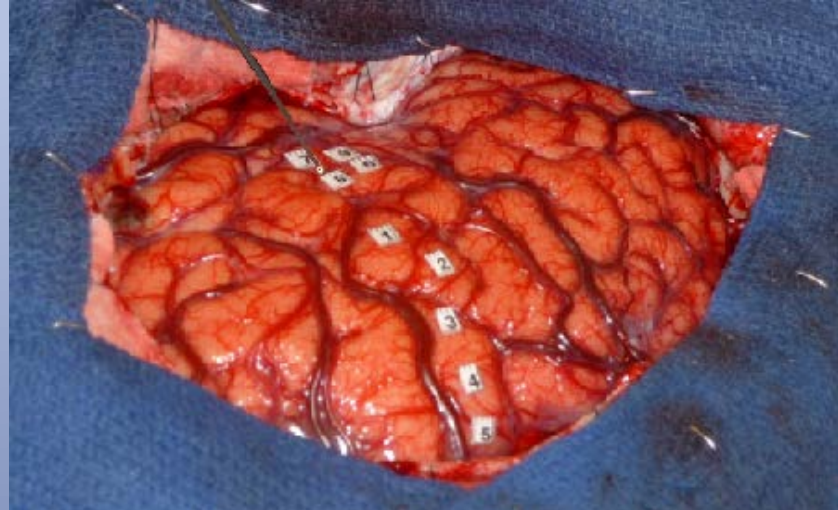
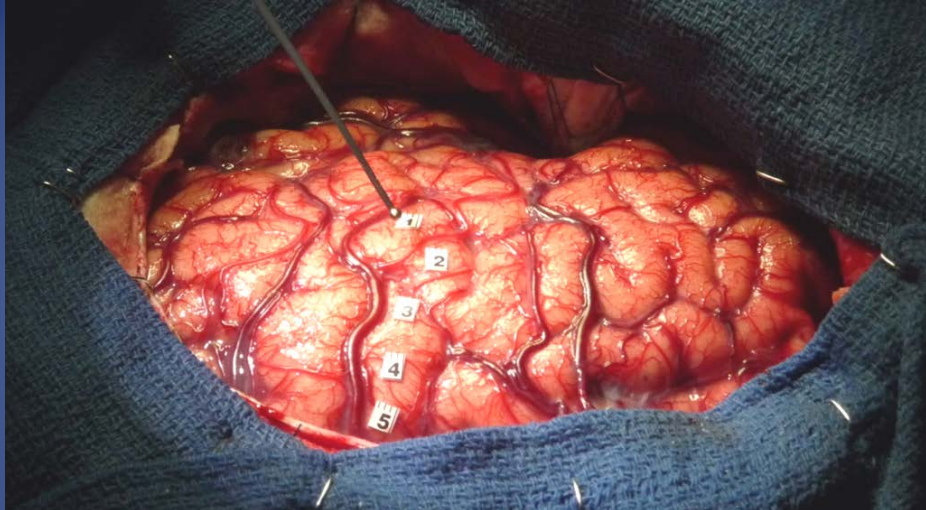

- Standard MN Phase reversal utilized to locate central sulcus

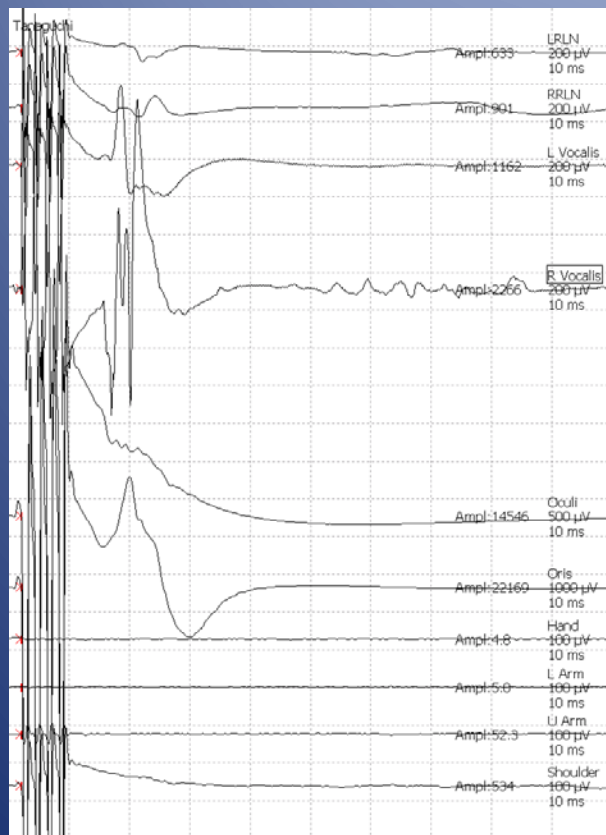


Anodal, Monopolar Motor Cortex Stimulation

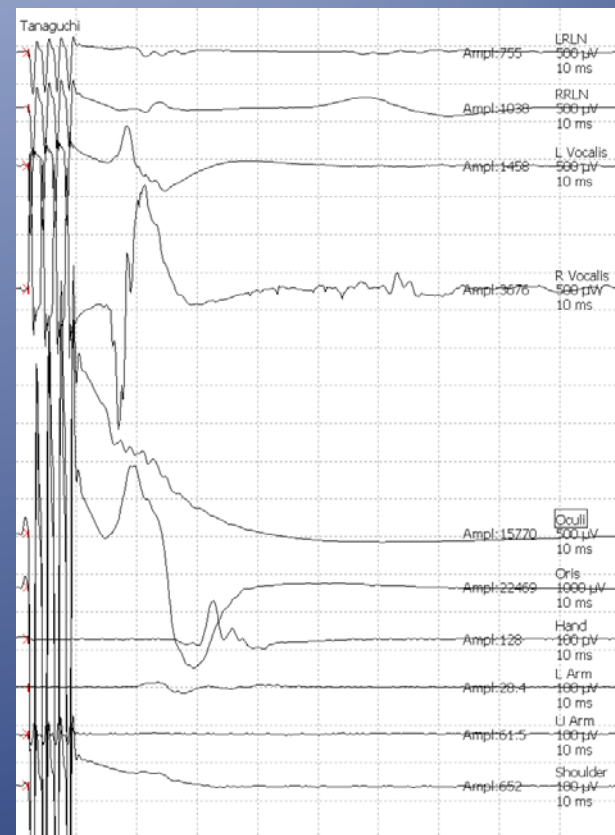




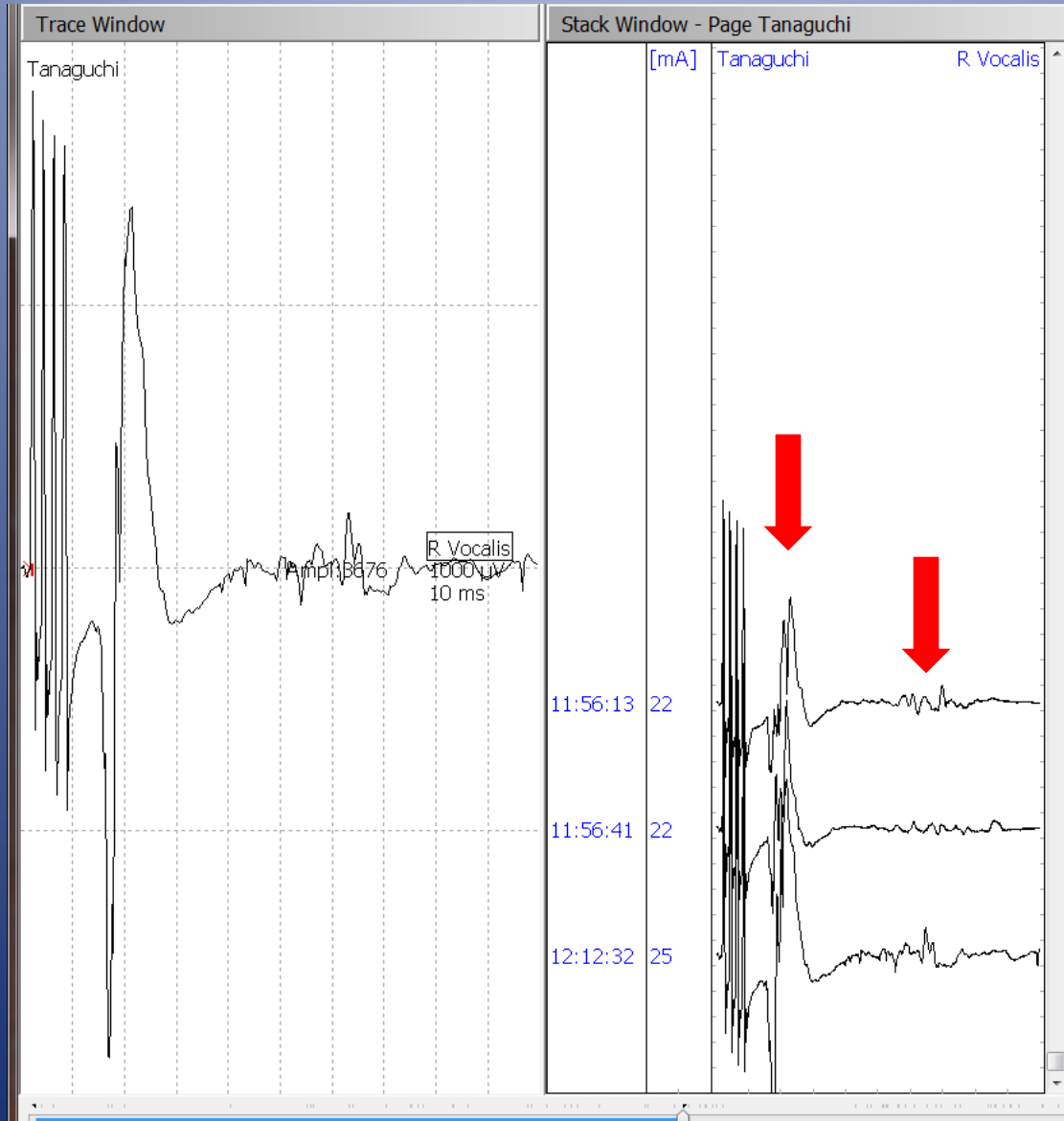
22 mA, monopolar



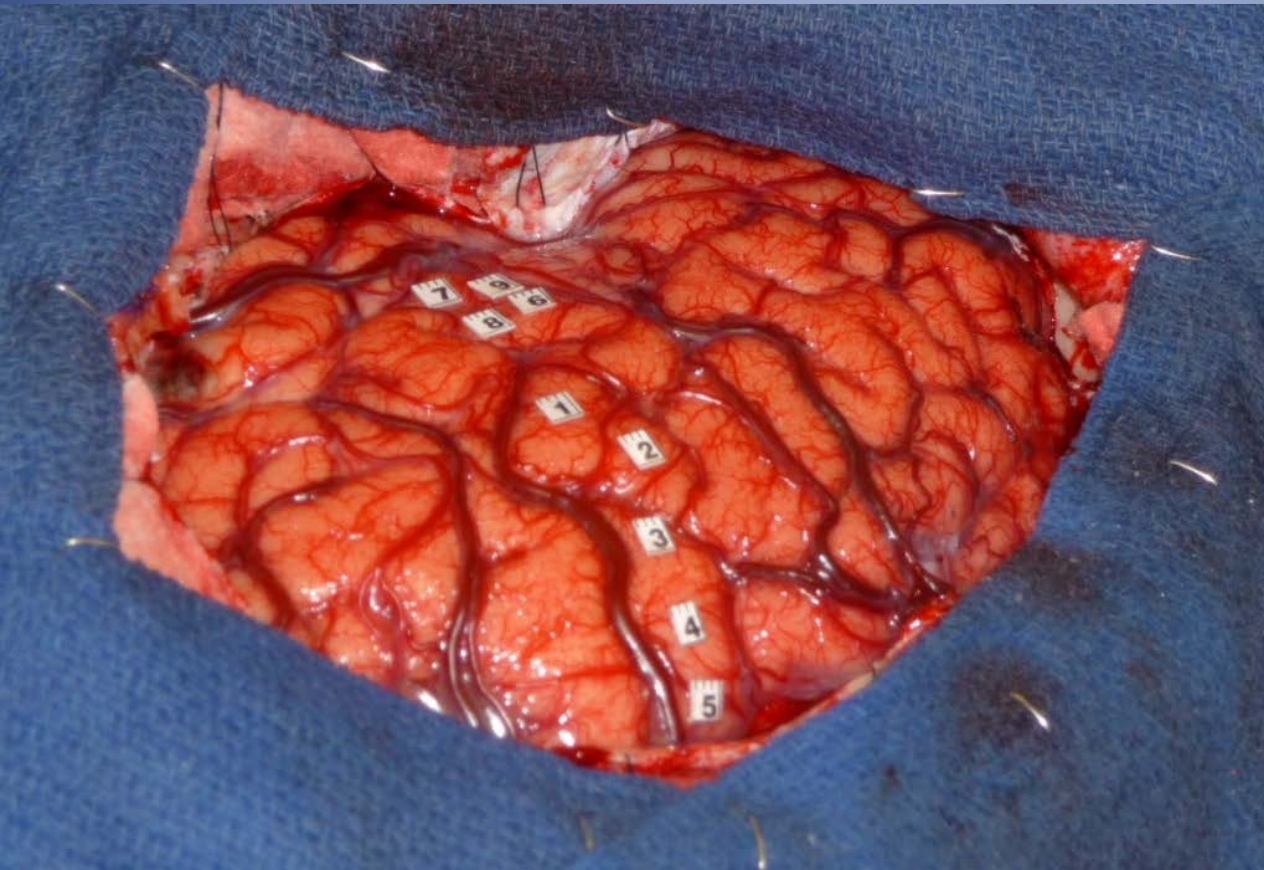
25 mA, monopolar



Short and Long Latency Vocalis Responses



Mapping Results



6,7,8,9 = Oris and Right
Vocalis (SLR&LLR)

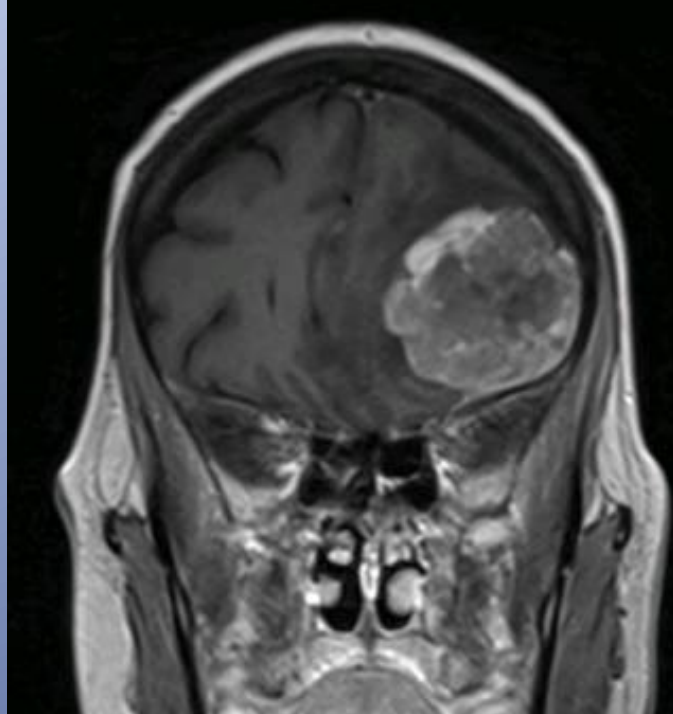
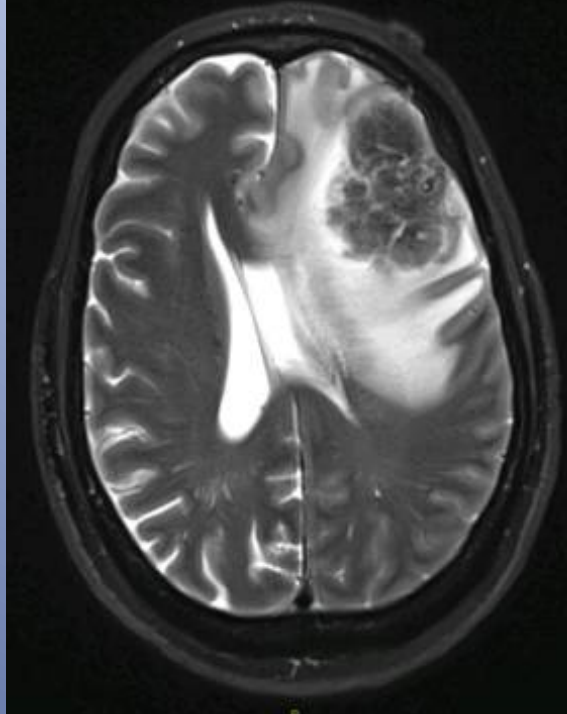
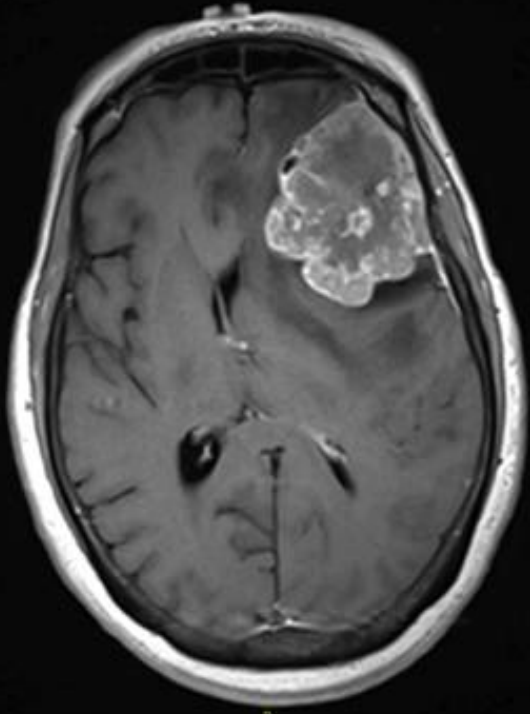
1 = Oculi/Oris

2,3 = Hand

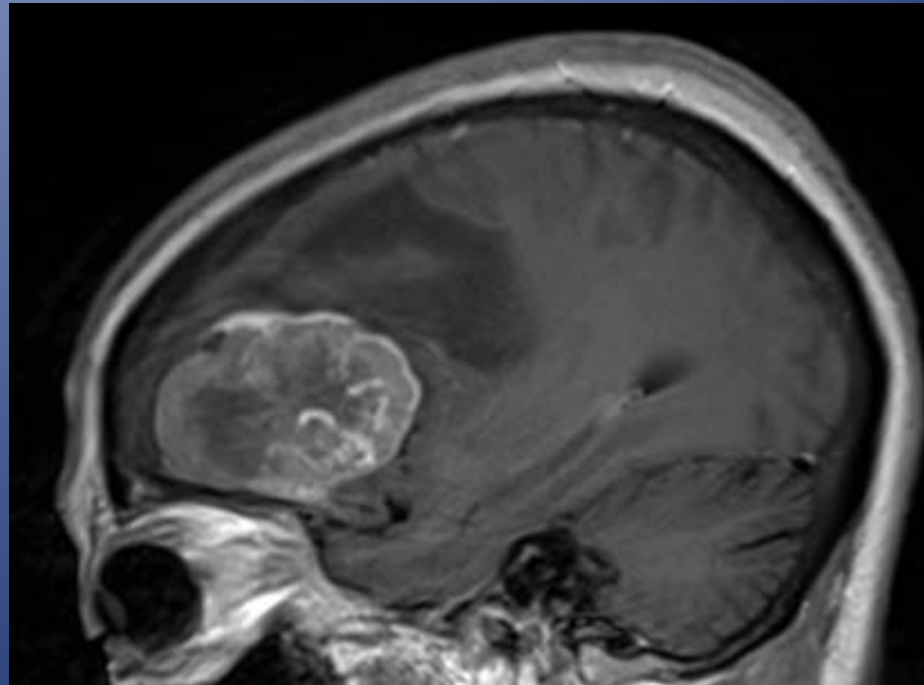
4,5 = Arm/Shoulder

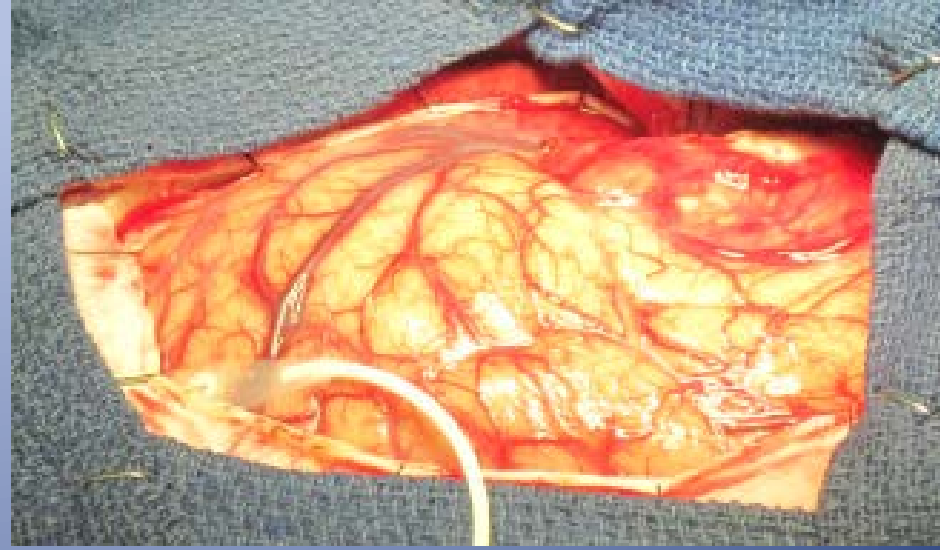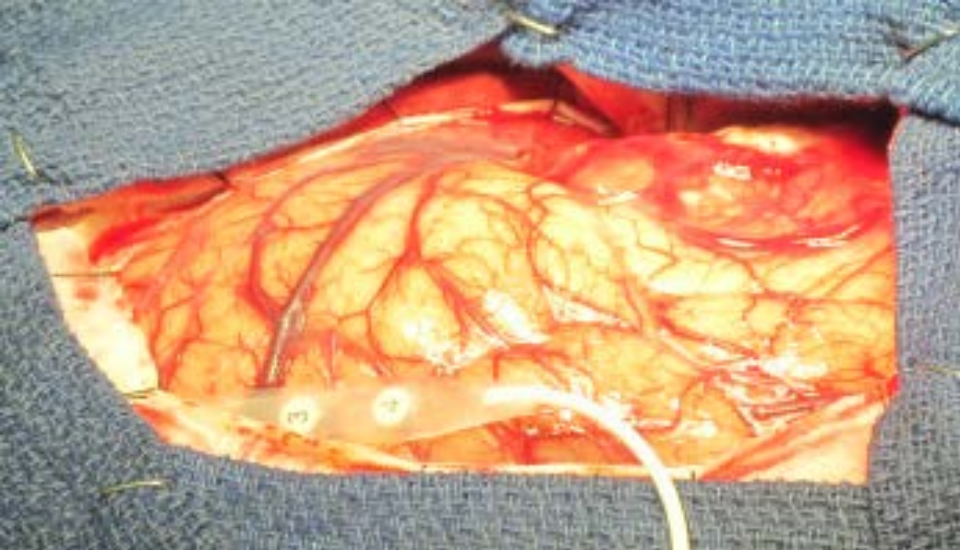Patient 2

- 59 y.o. female
- Large left frontal tumor
 - Metastasized adenocarcinoma from colon cancer
- Patient has been falling down
 - Demonstrating progressive right arm weakness and problems verbalizing

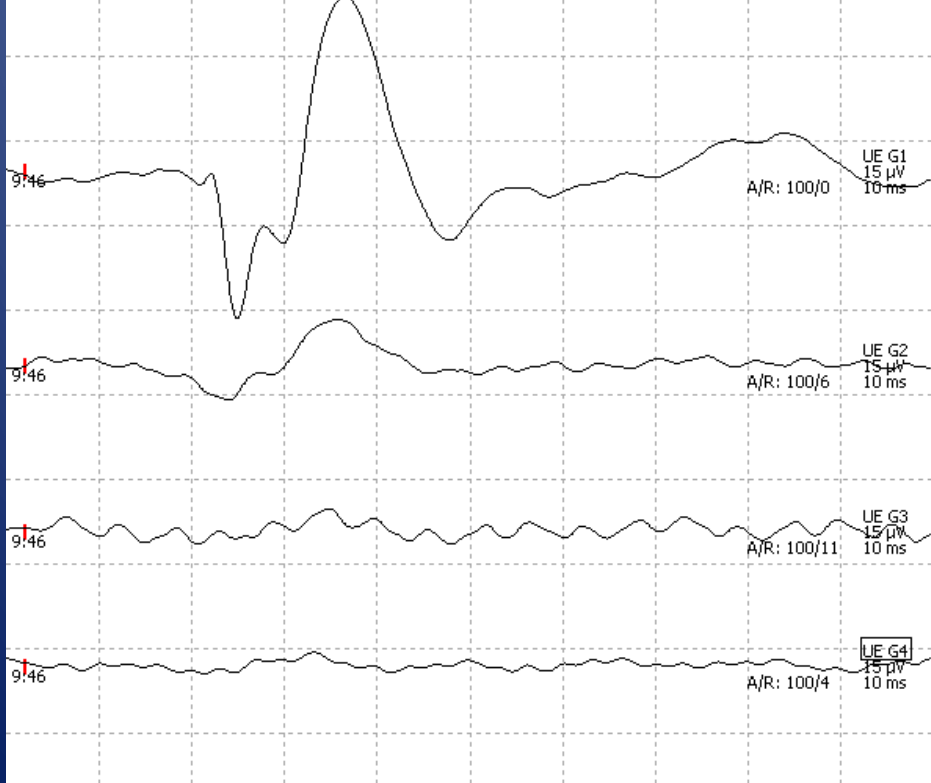


Tumor Images

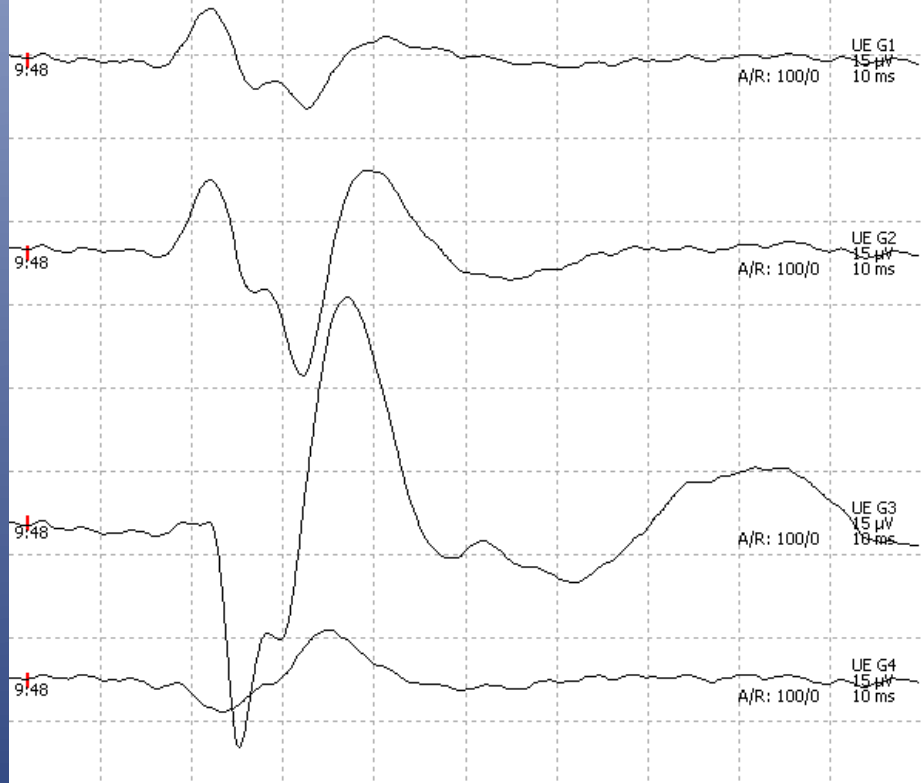




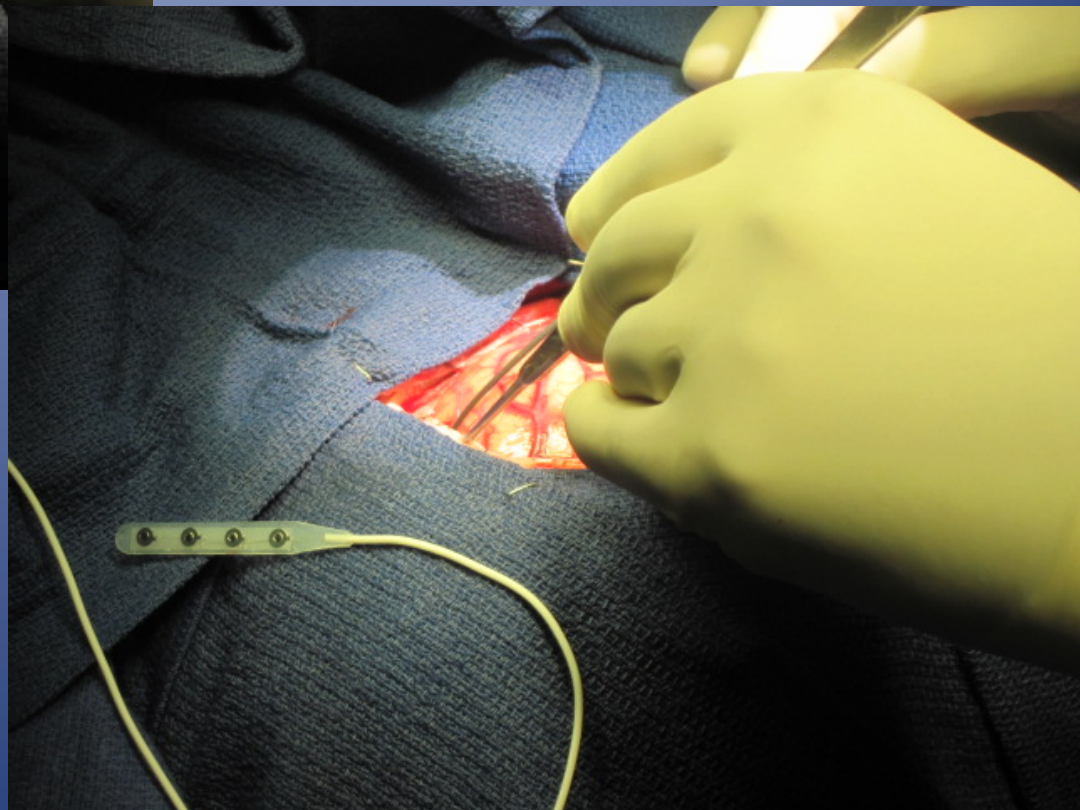
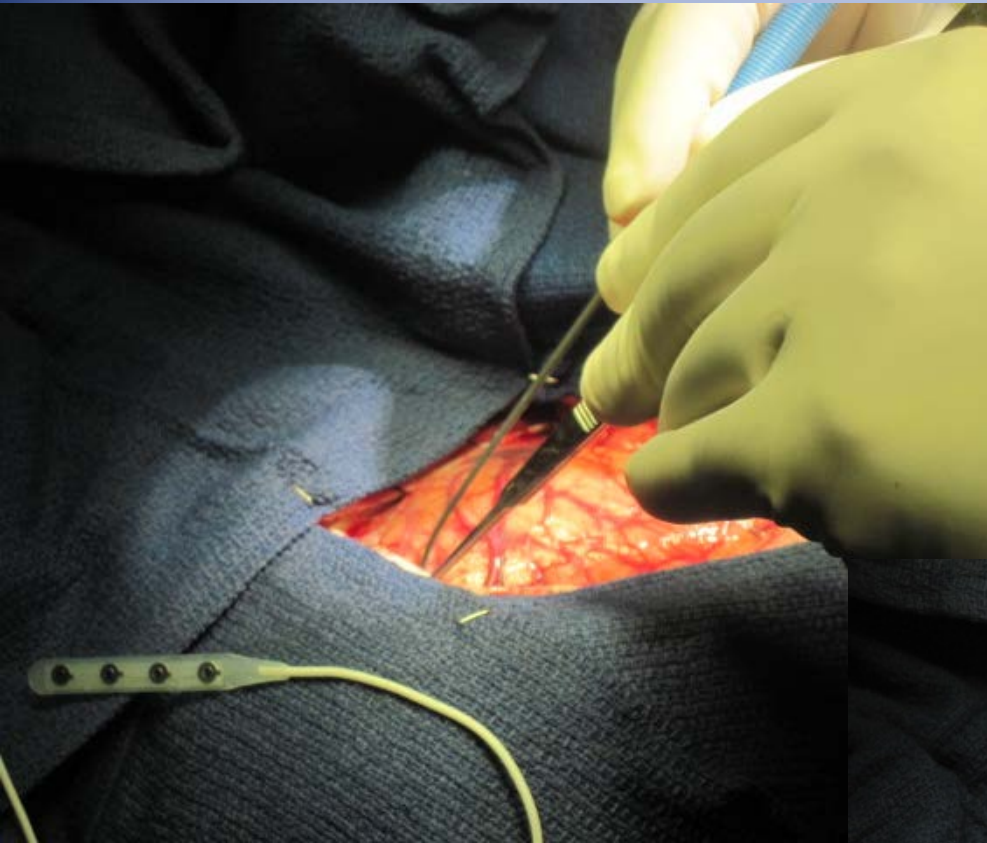
MN PR

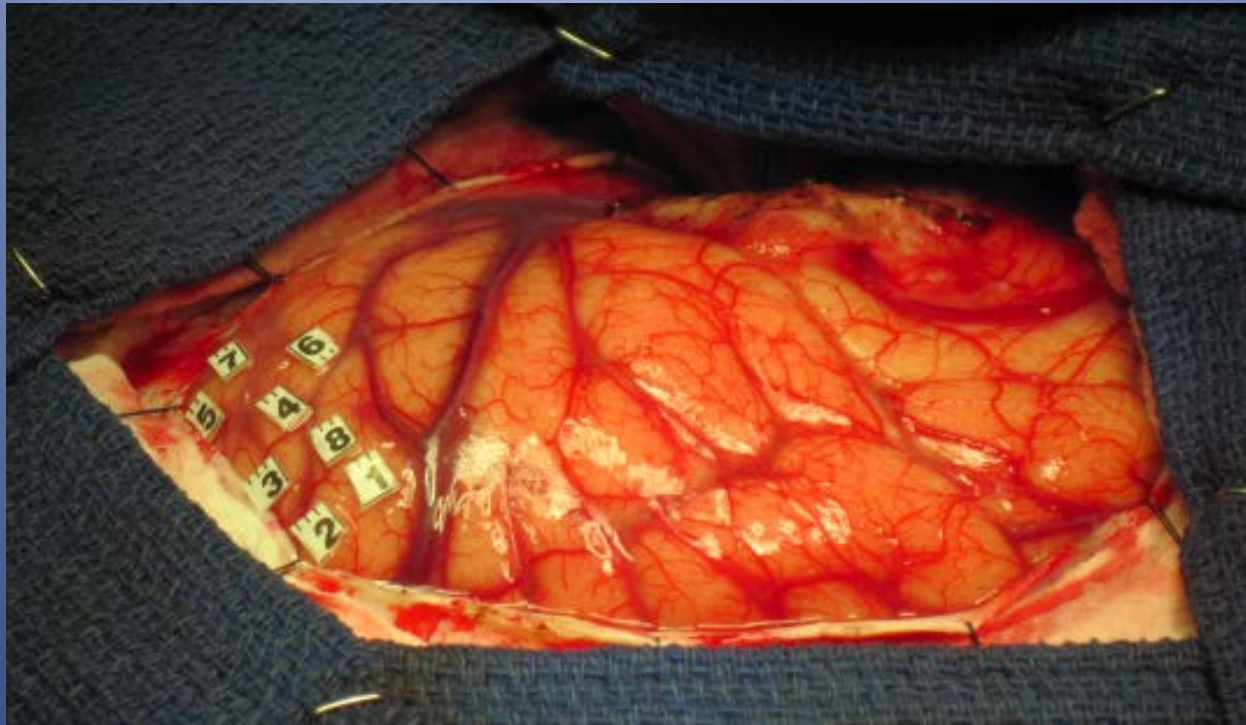


MN PR

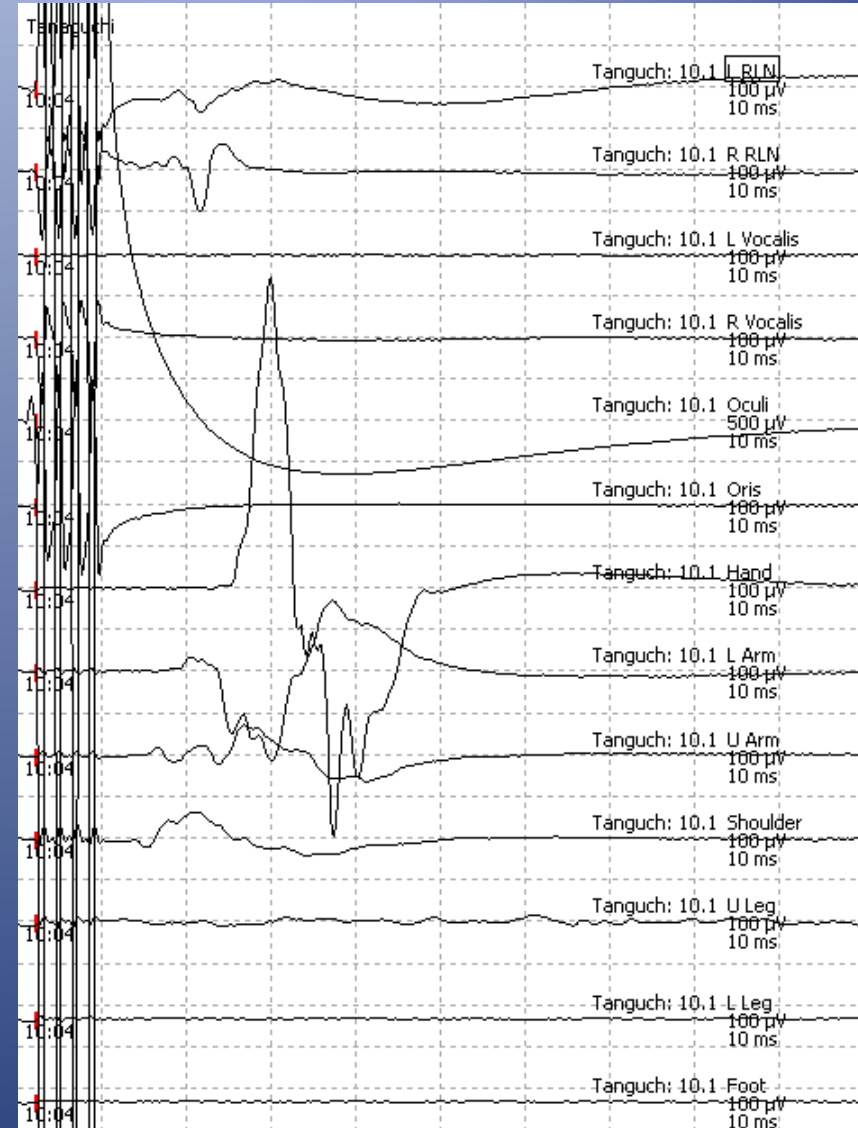
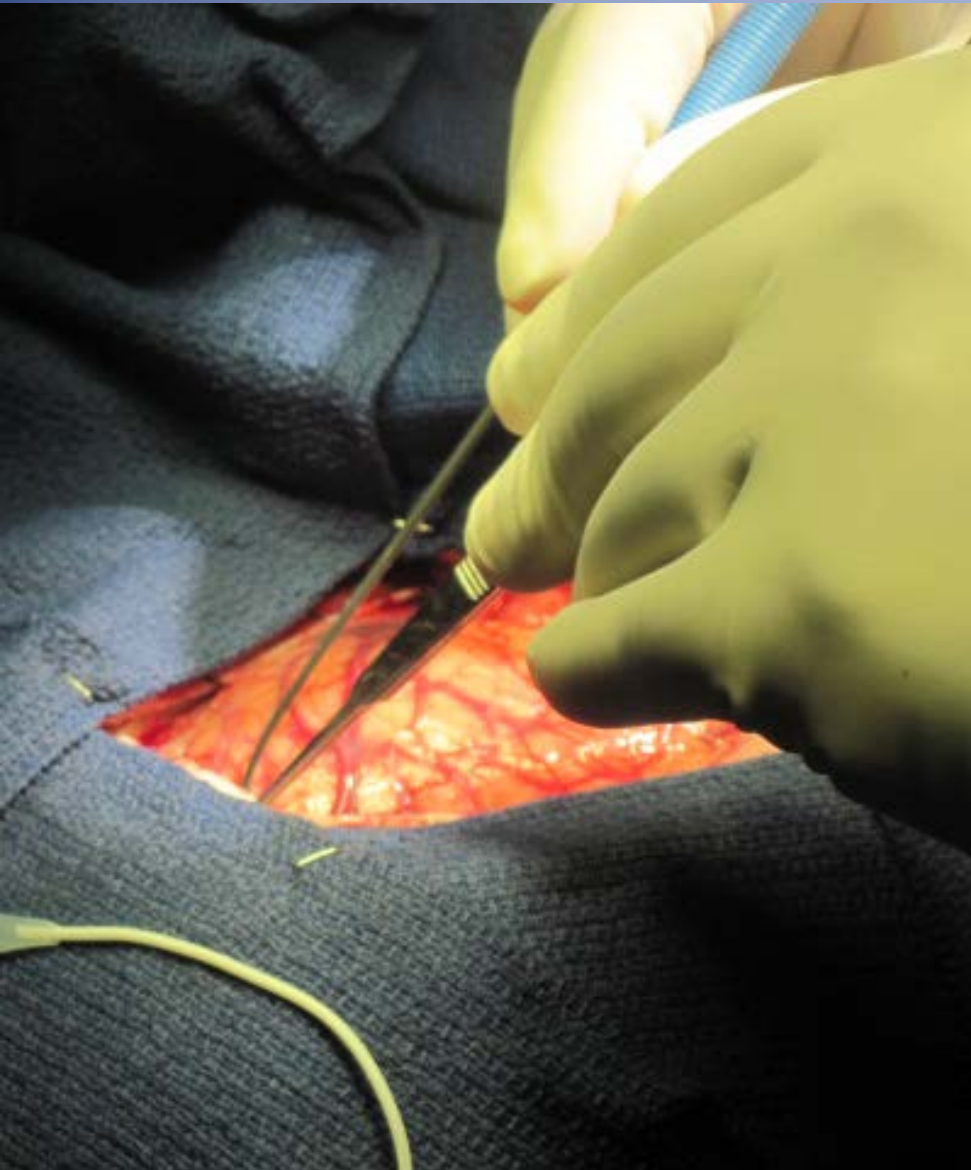


Initial mapping at posterior edge of exposure near the identified motor strip

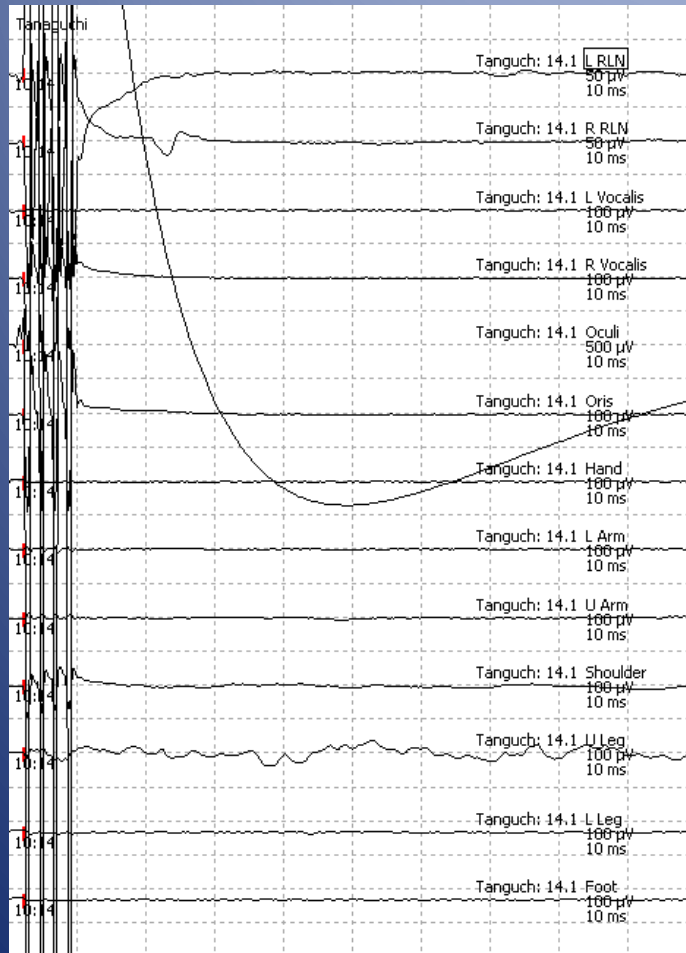




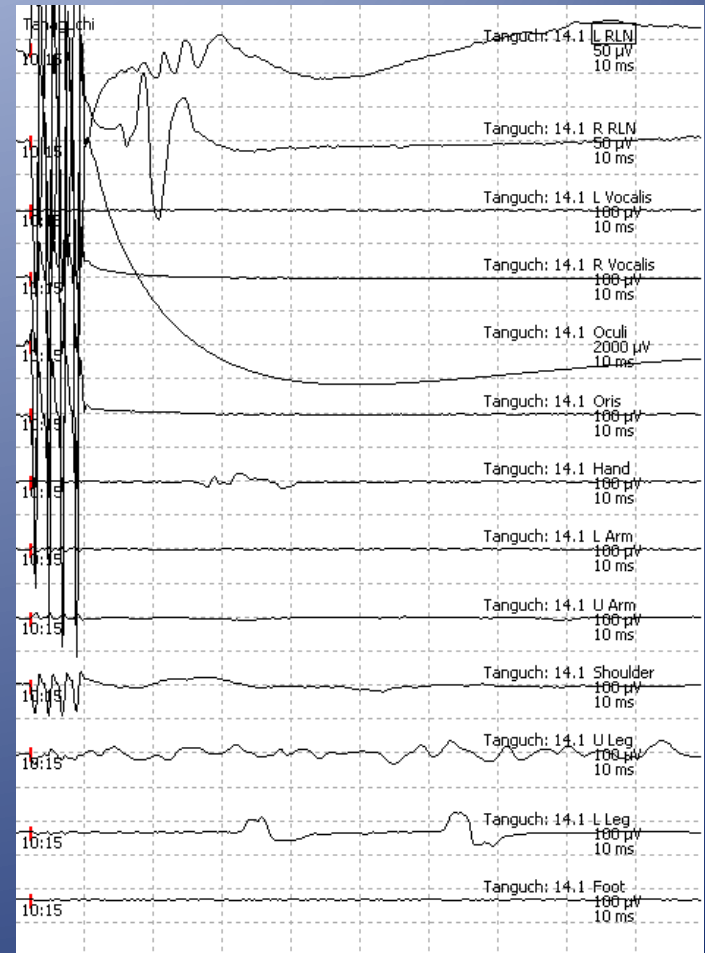
Initial Mapping Produced Upper extremity and Laryngeal Response (labeled “RLN”)



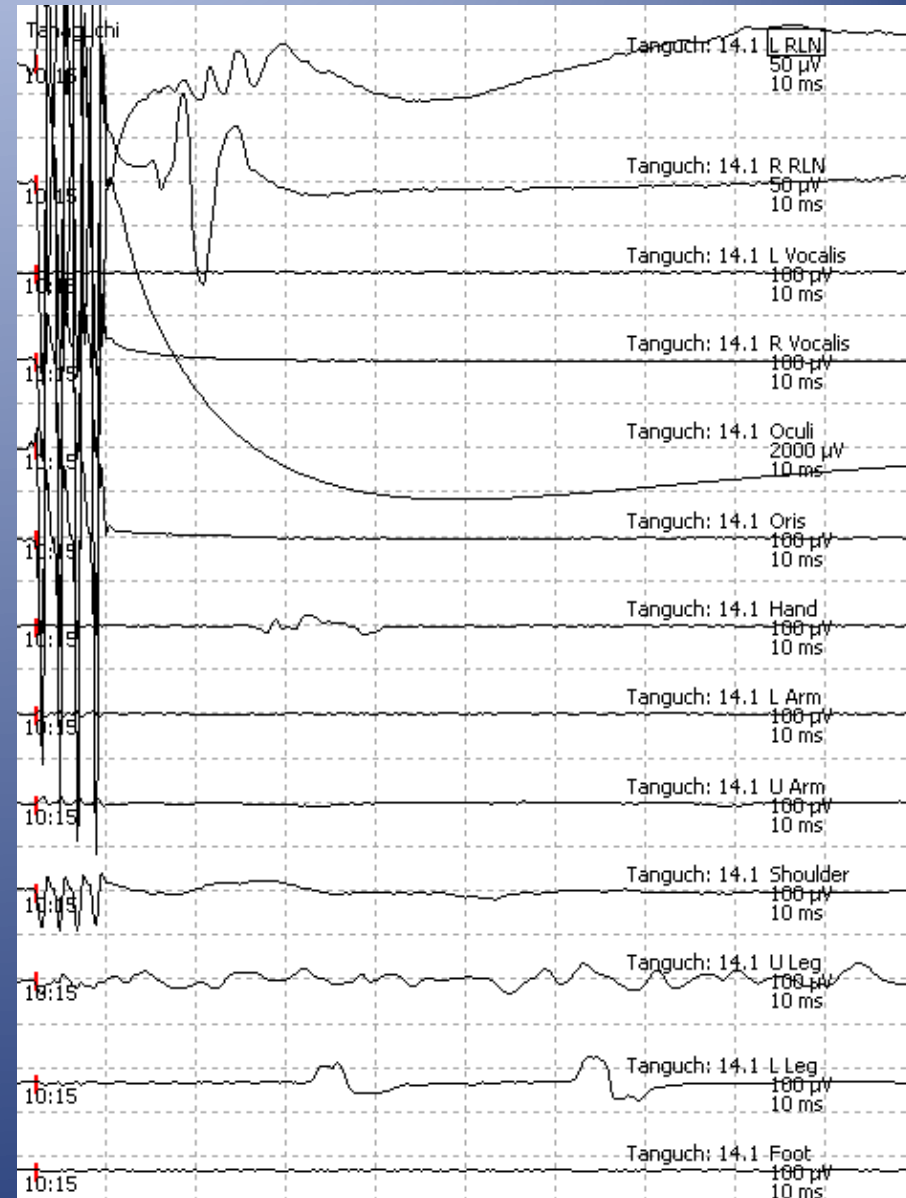
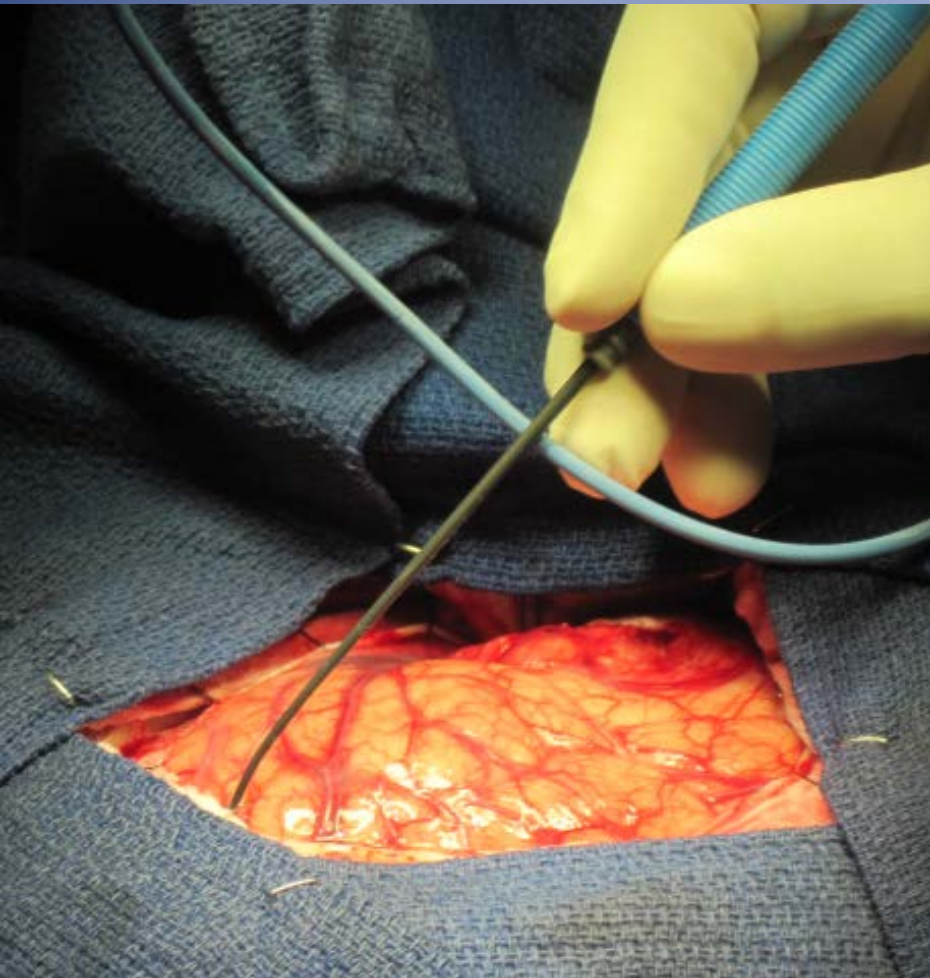
#1



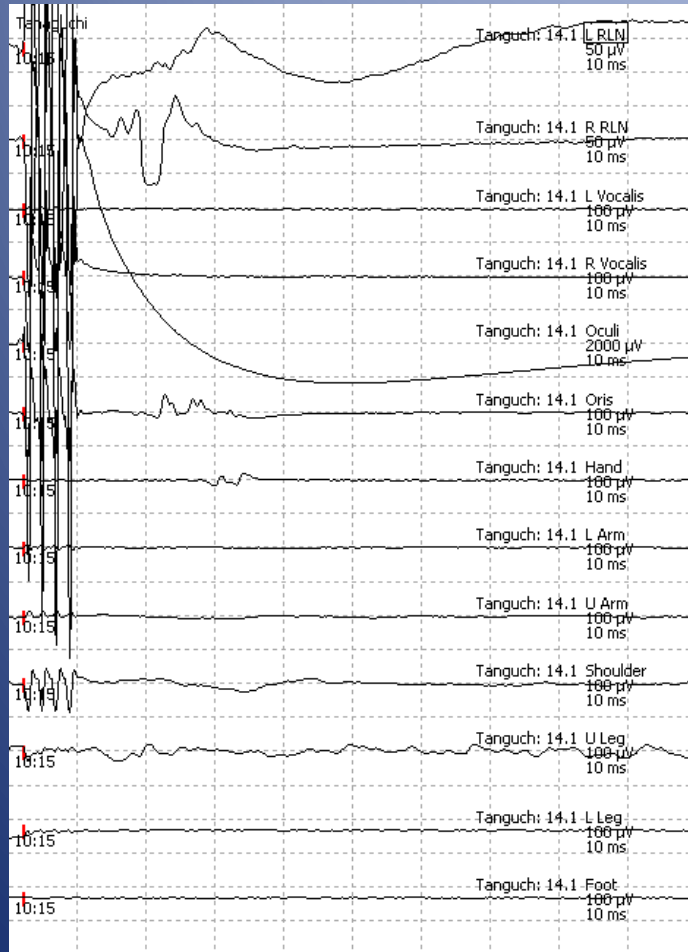
#2



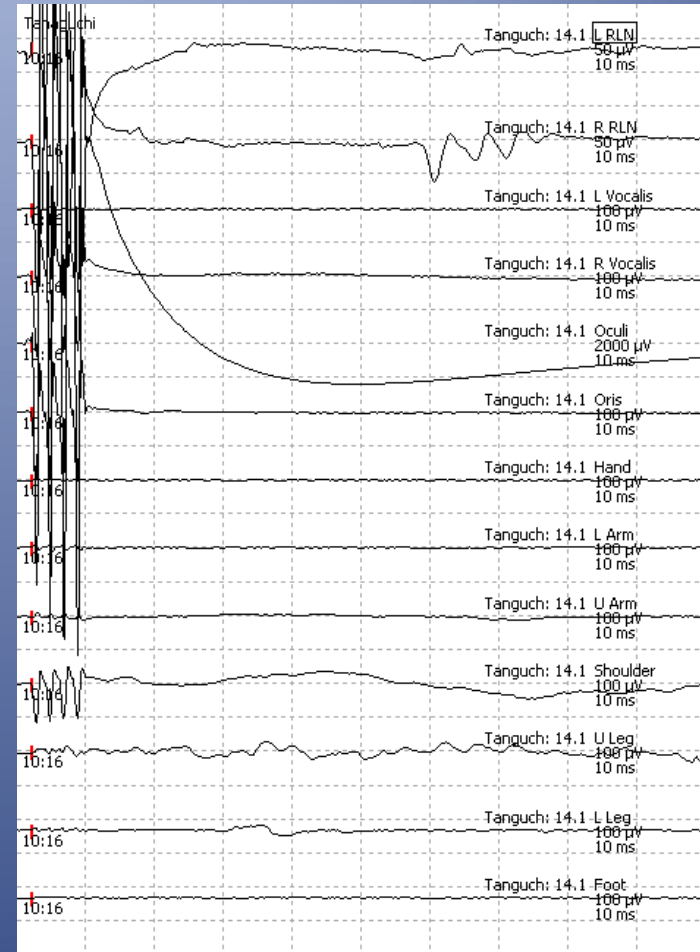
#2 Site yielded short latency Laryngeal response



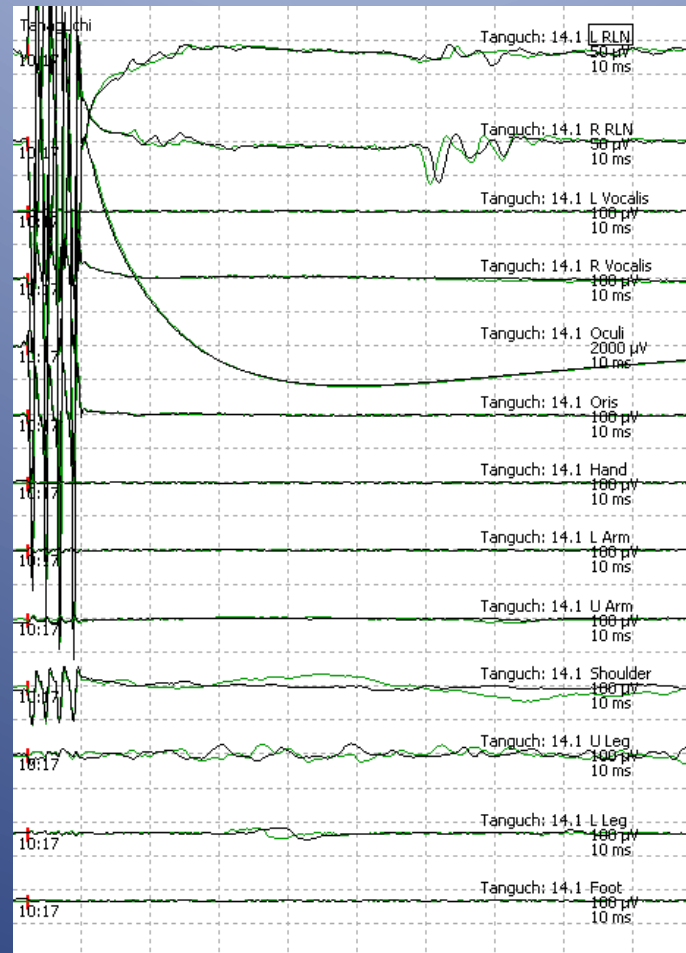
#3



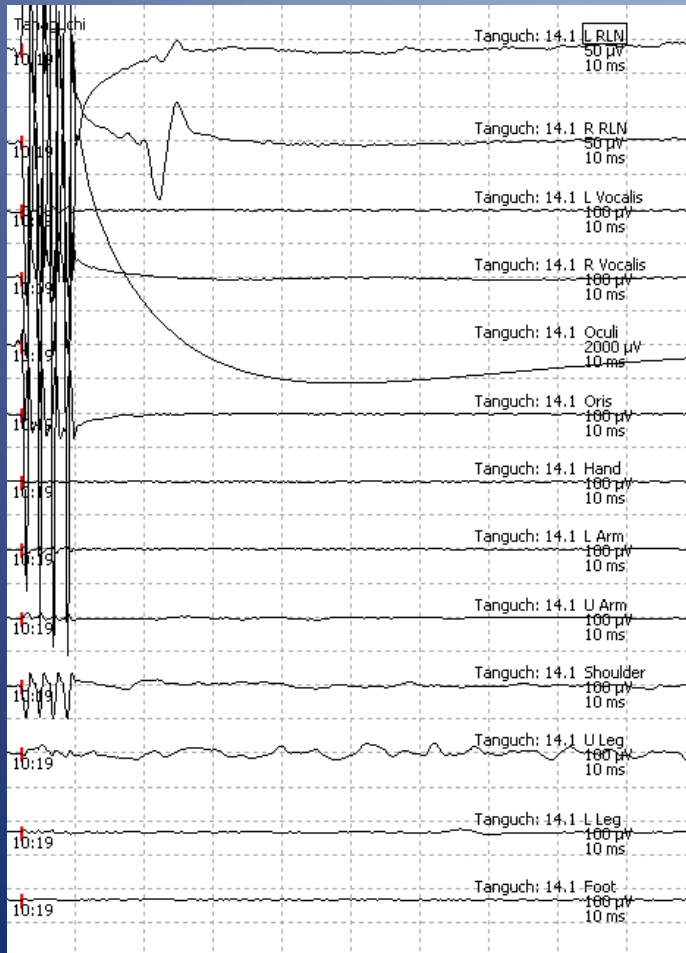
#4 – Long latency response



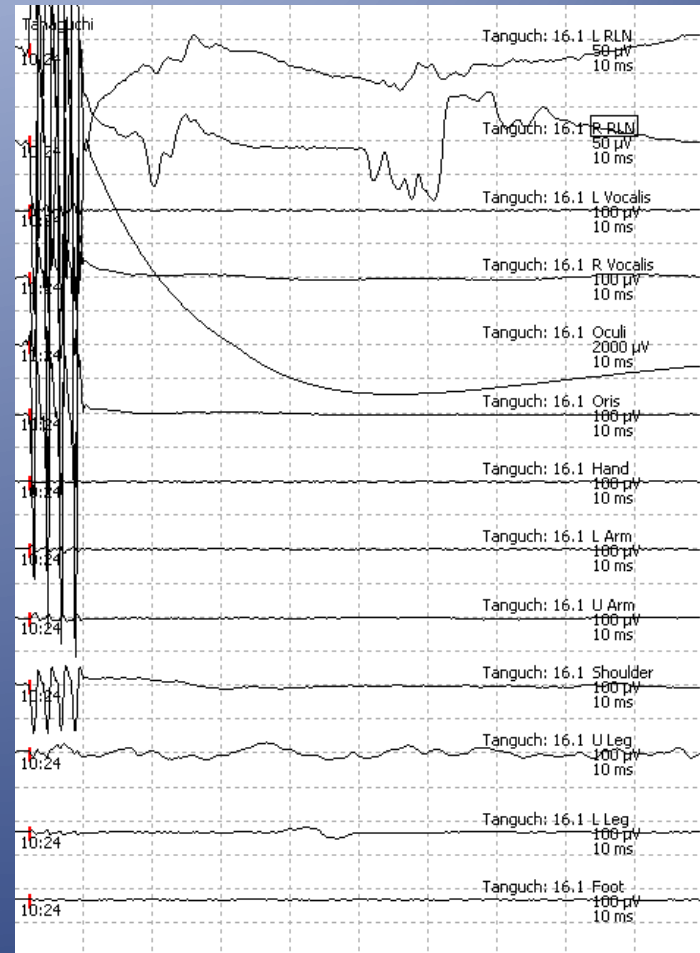
#4 replication larger amplitude LLR



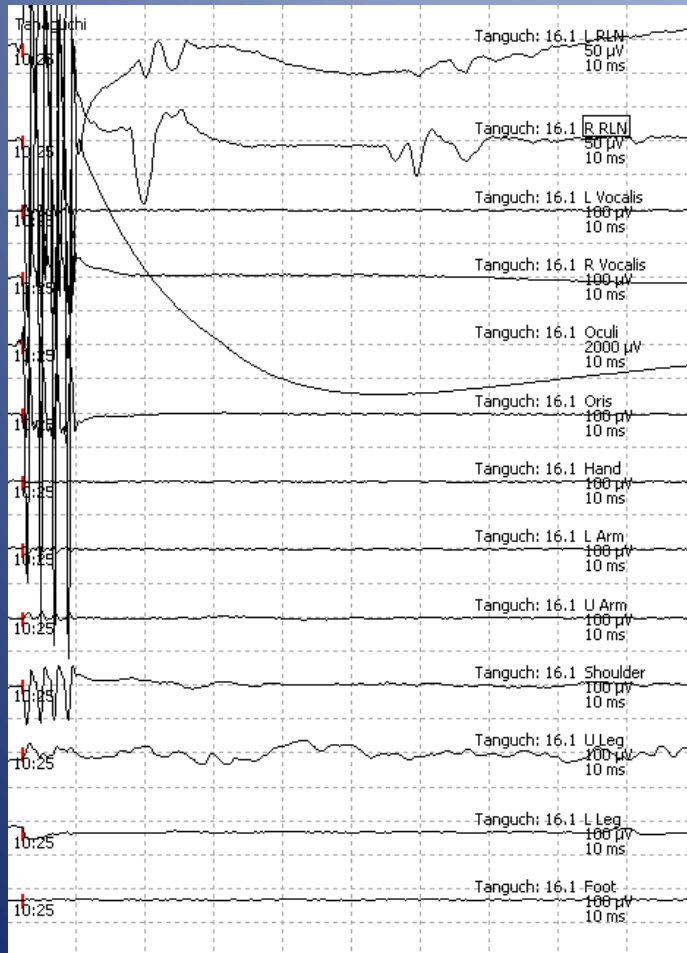
#5



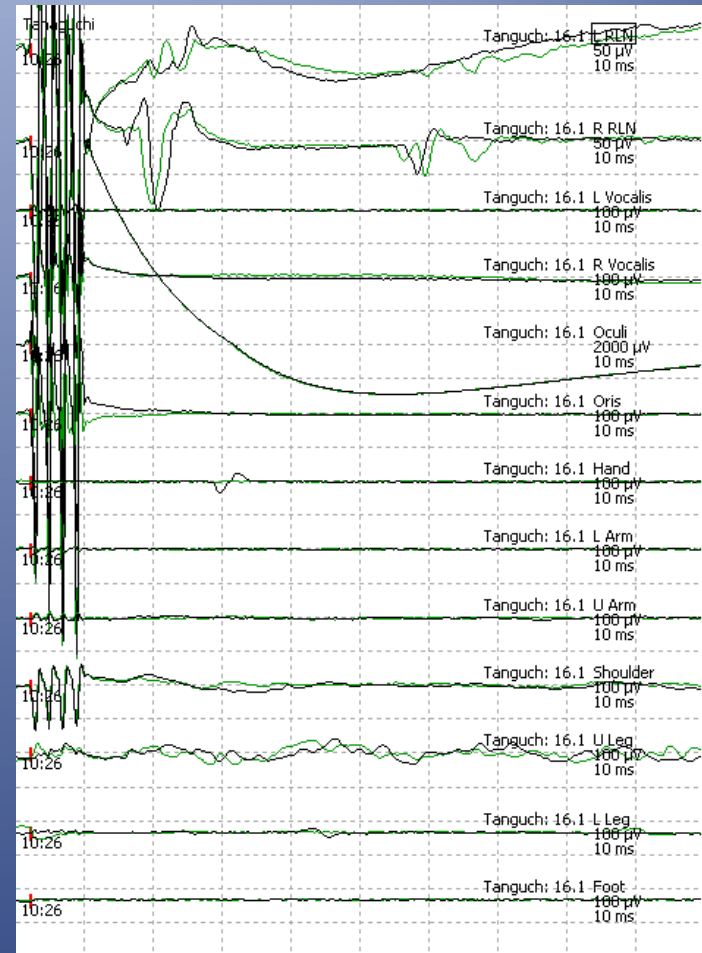
#6



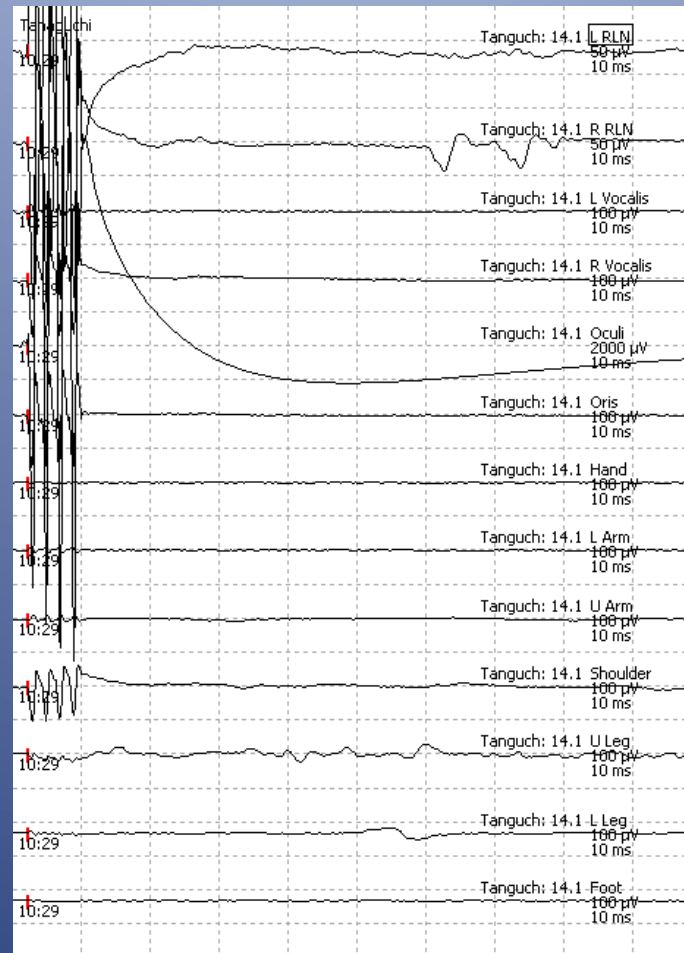
#7

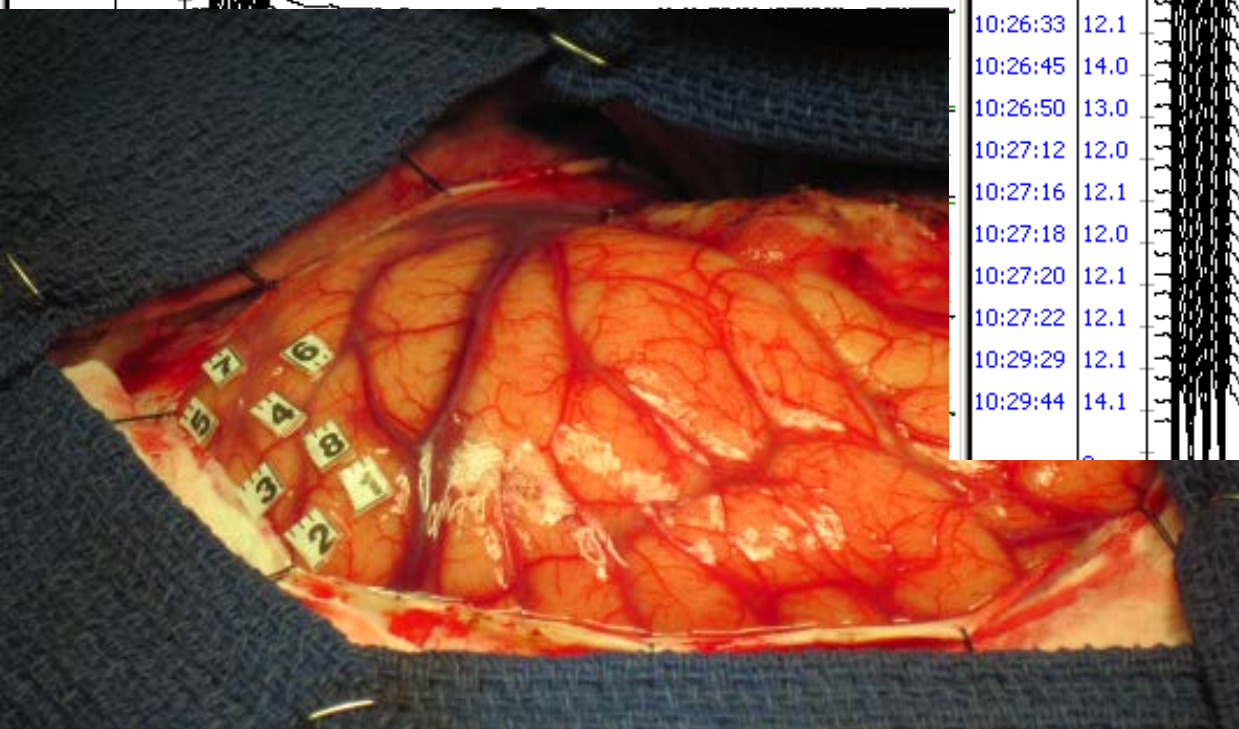
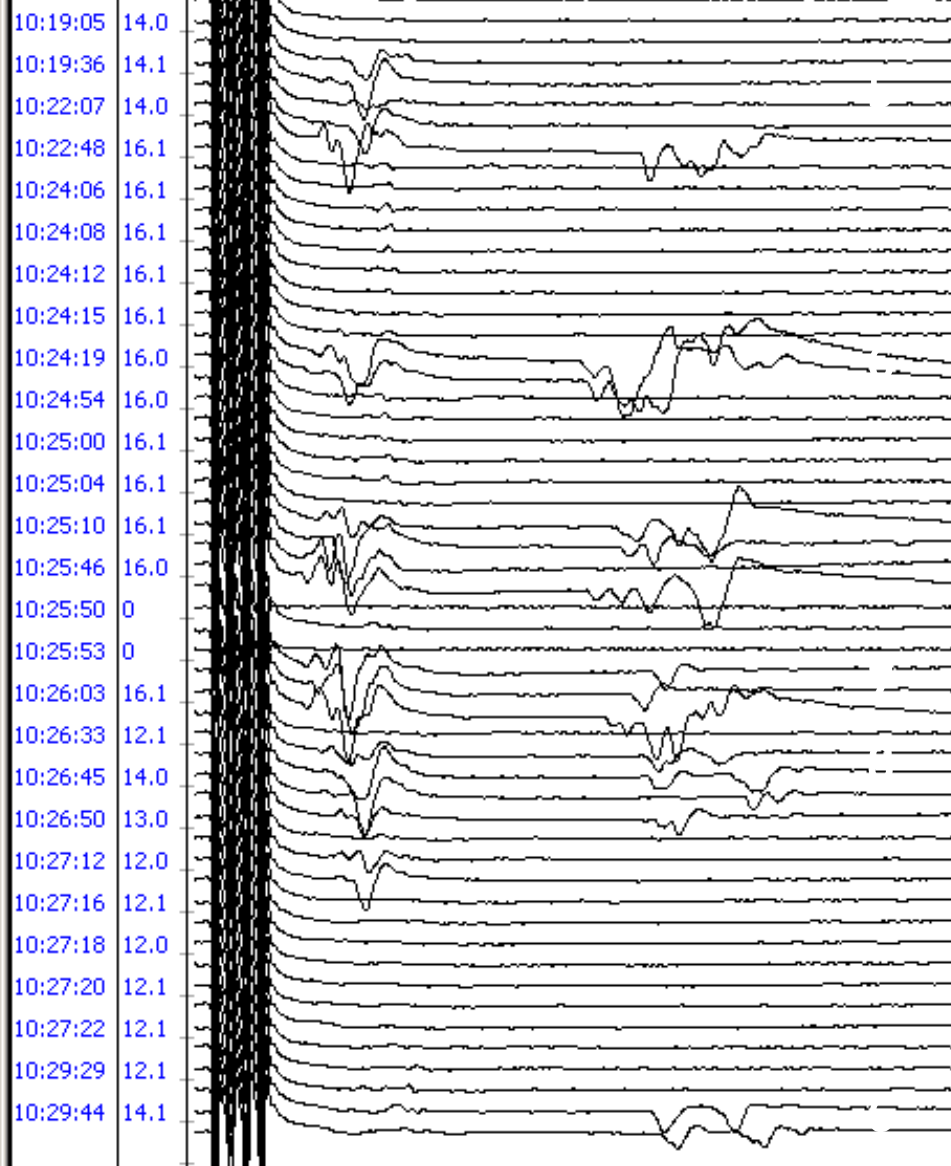
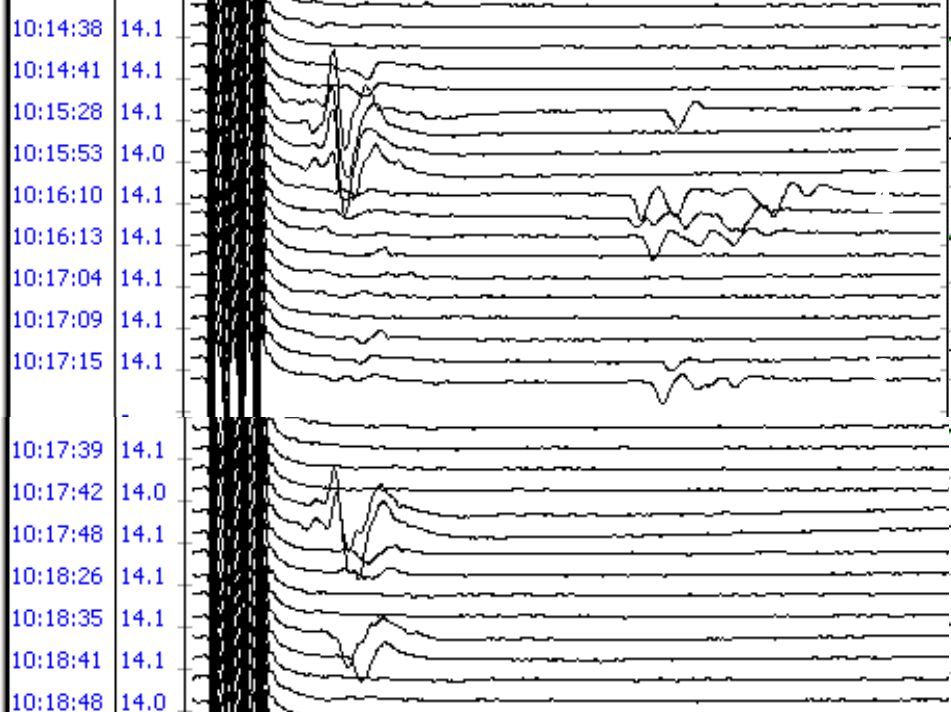


#8



#6 – LLR only at 14 mA





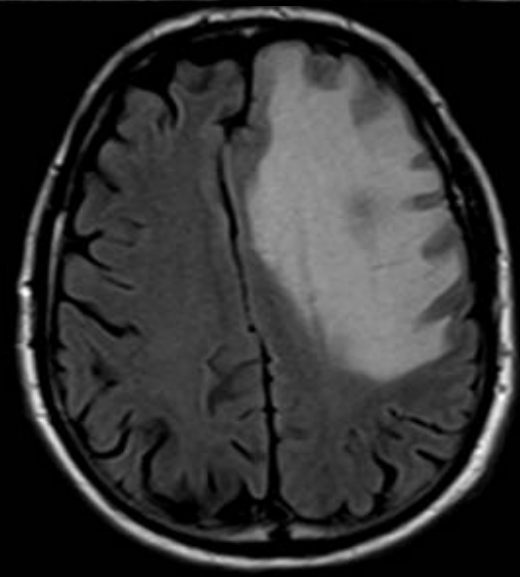
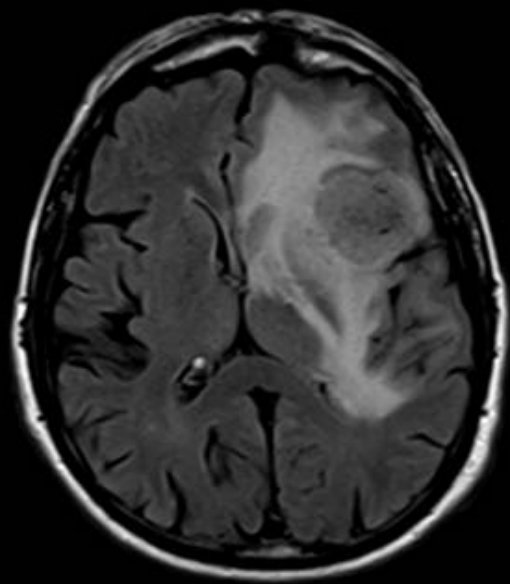
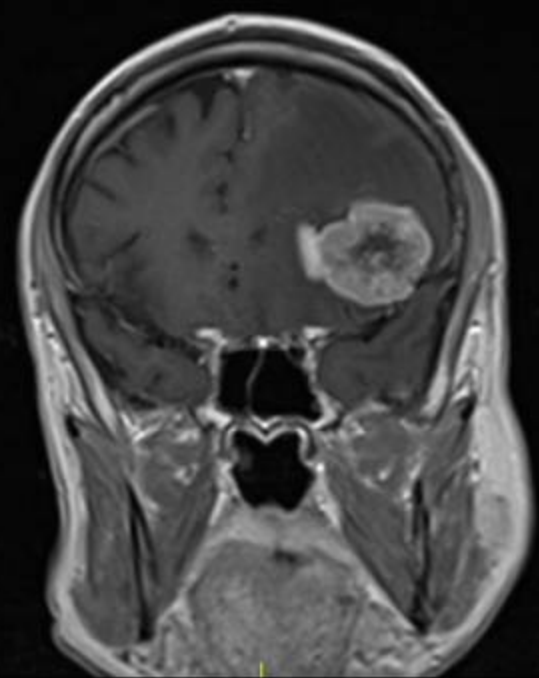
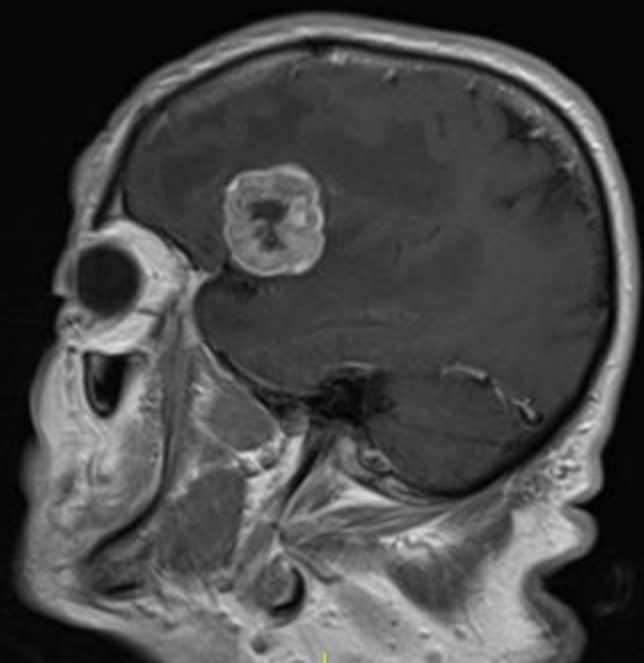
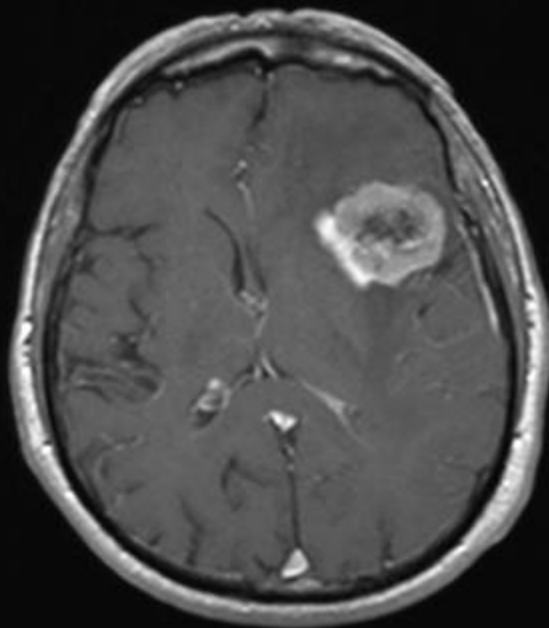
LLR was isolated to #6 at 14 mA. Increase in intensity caused spread and inclusion of SLR

Pearls and Pitfalls

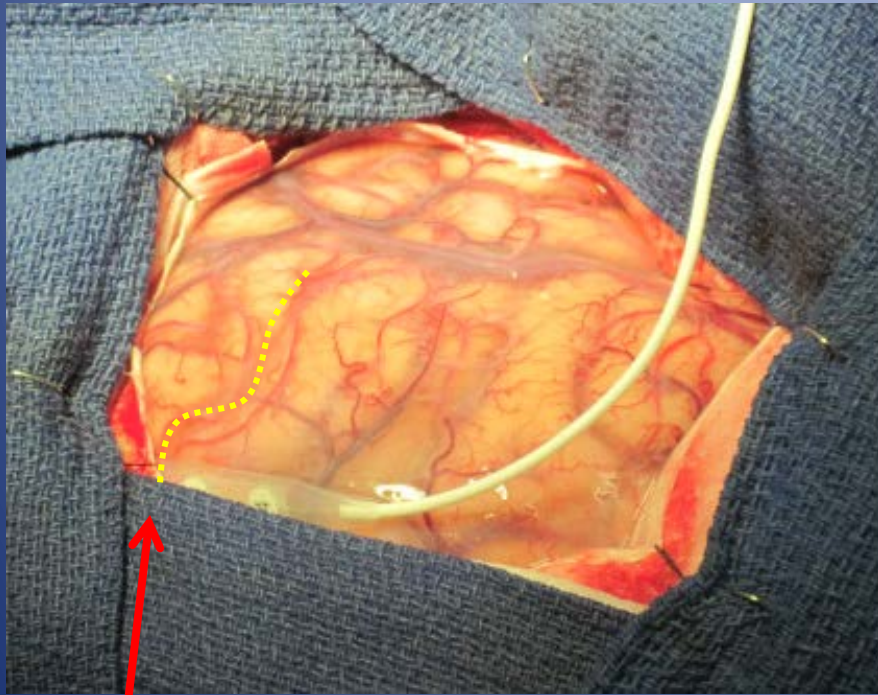
- Hookwires failed to record any useful data on this case
- ET Tube recording was successful
- Both electrodes must be placed!
- To isolate the long latency response, careful titration of monopolar stimulation is necessary to avoid current spread
 - Bipolar stimulation may solve this problem

Patient 3

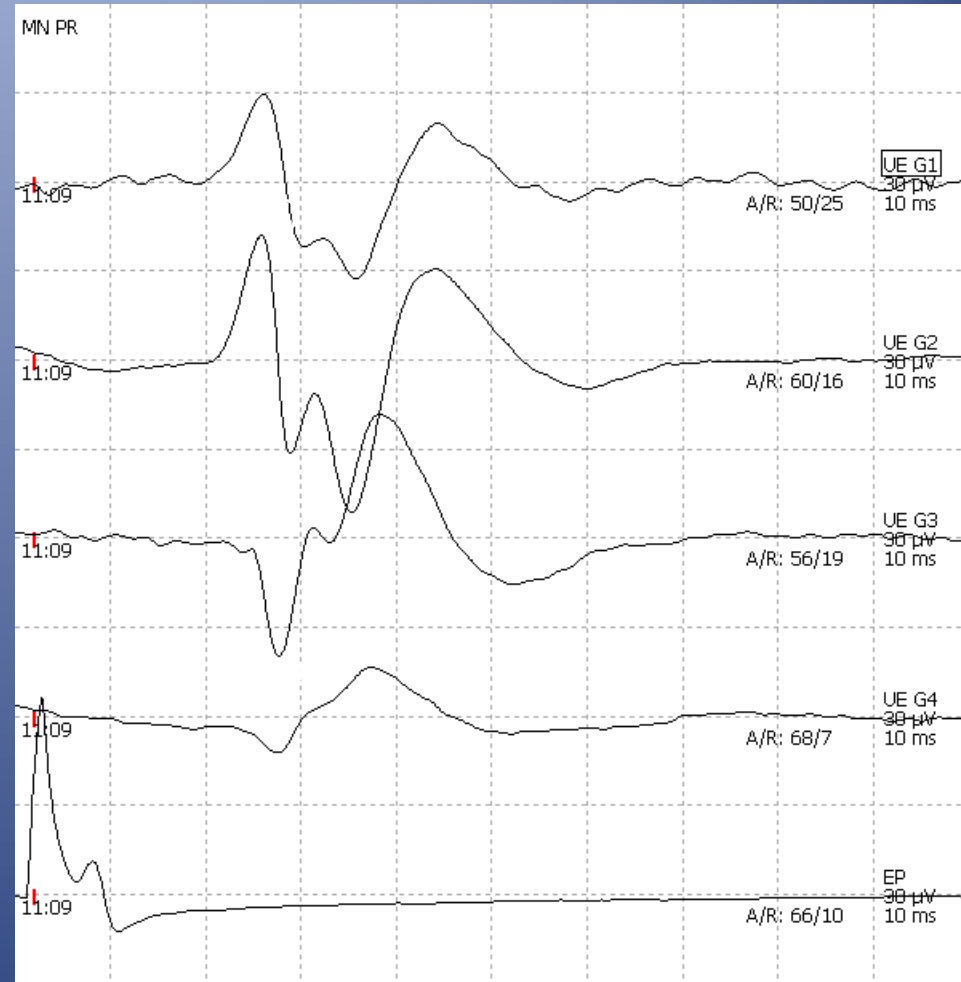
- 79 y.o. male
- Presented with speech deficits
- Large (4-5cm) left frontal tumor over Broca's area on MRI.
- Significant surrounding edema and mass effect with 7-8mm midline shift.
- According to pts. daughter, his headaches and speech mildly improved after starting IV steroids.
- History of Merkel cell carcinoma (diagnosed 1 year prior) and recently had resection of a large mass involving the axillary lymph nodes. He underwent chemotherapy and a course of radiation therapy.

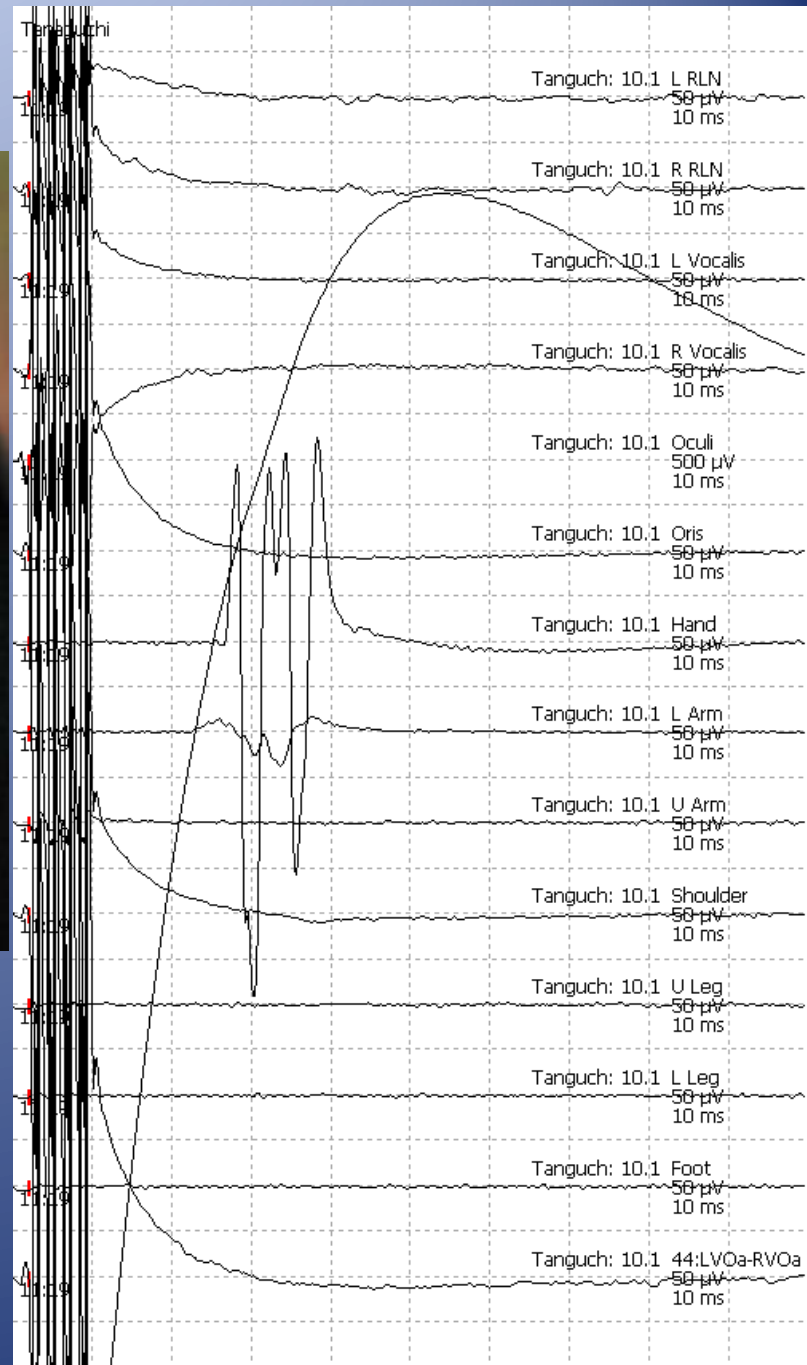
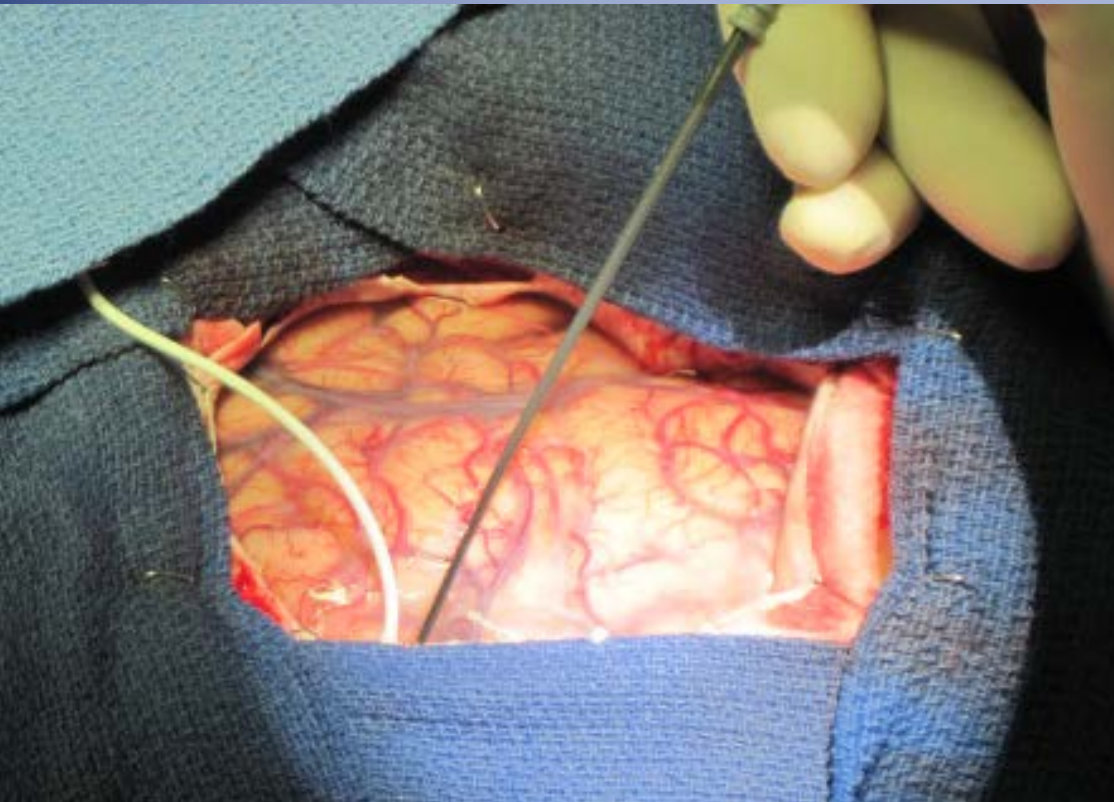


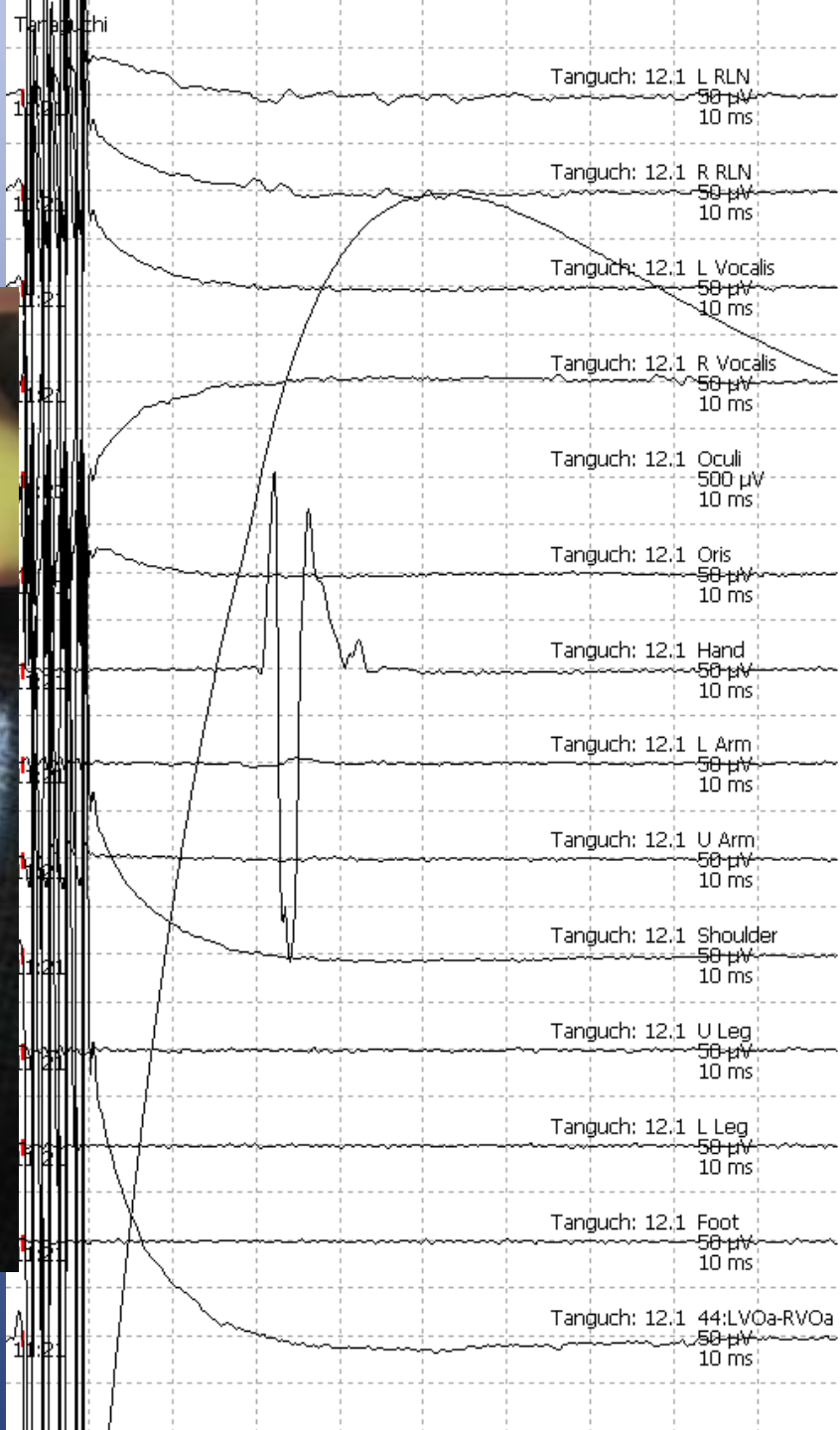
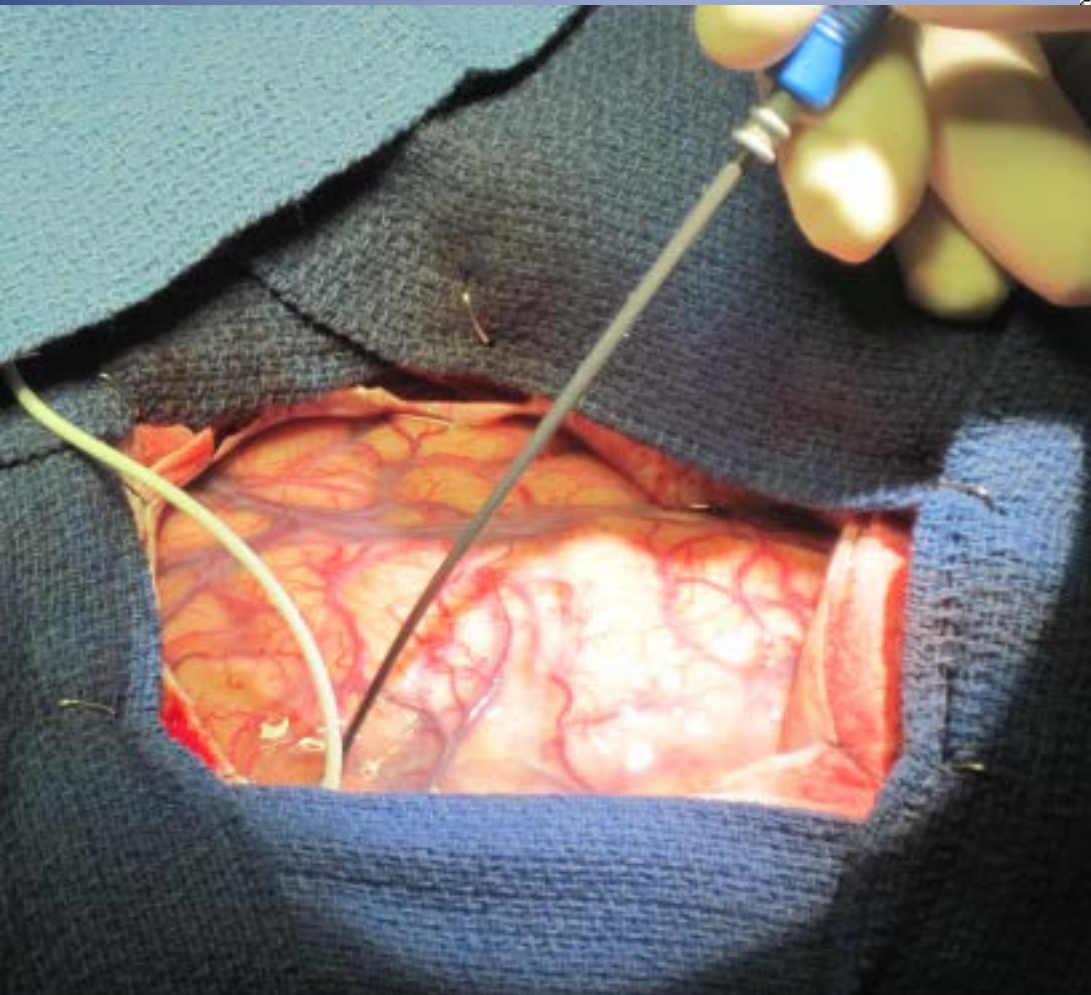
SSEP Phase Reversal

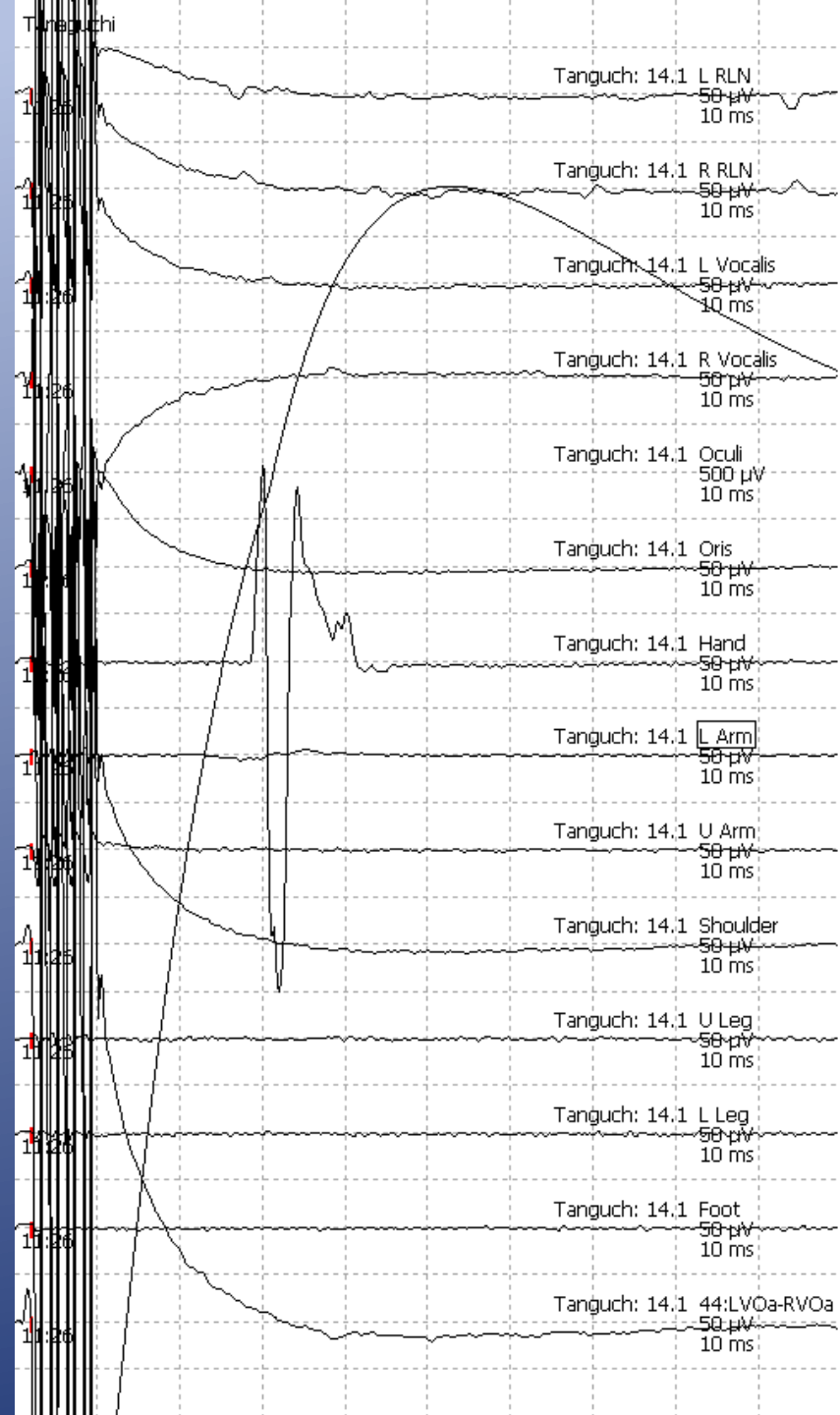
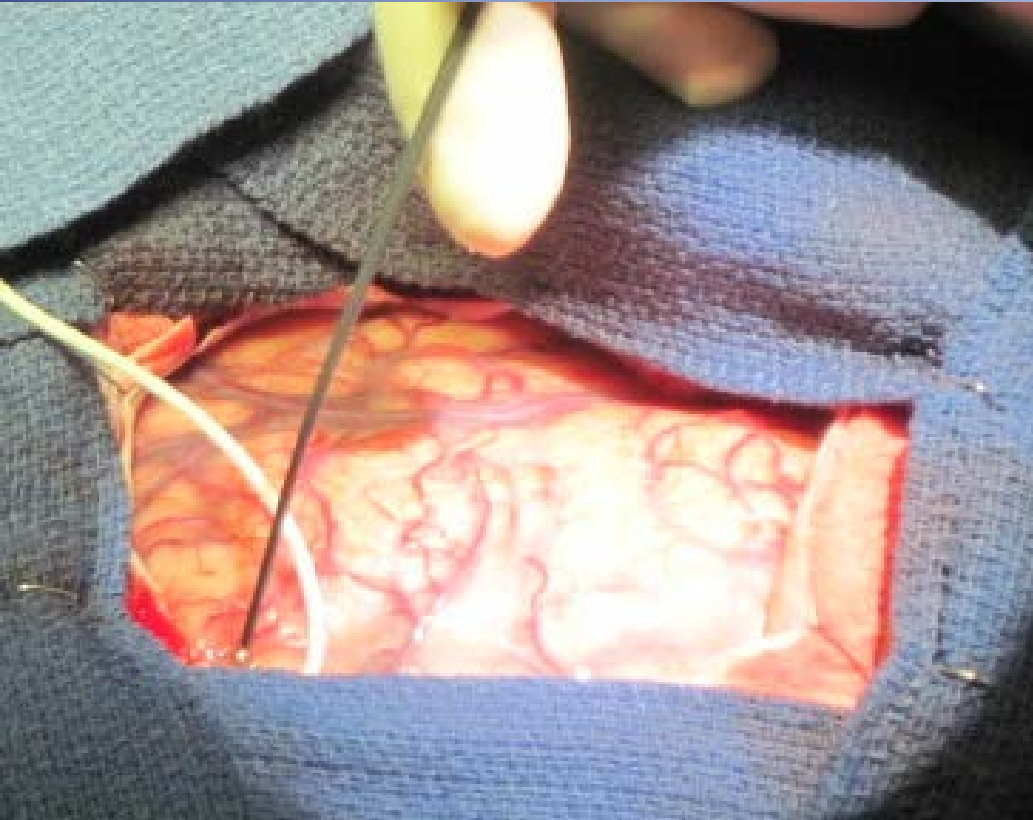

Central Sulcus

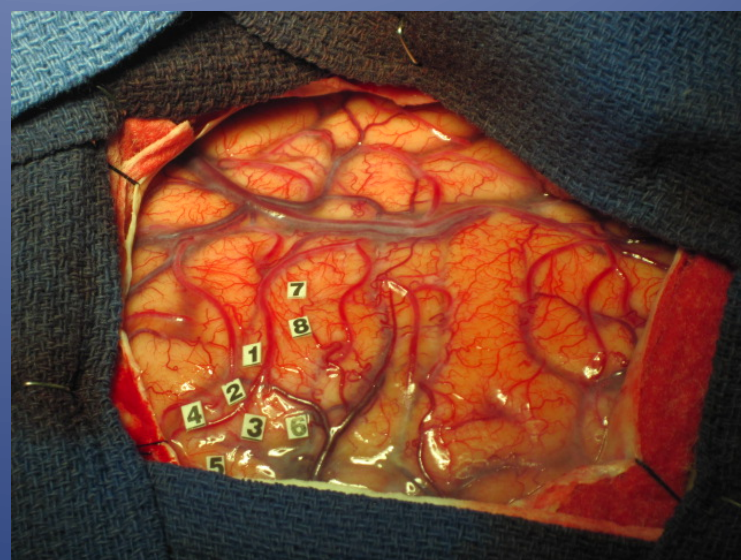
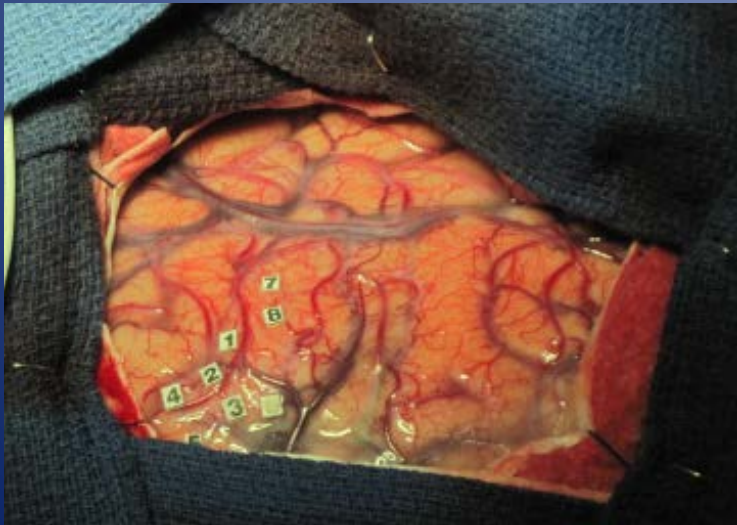
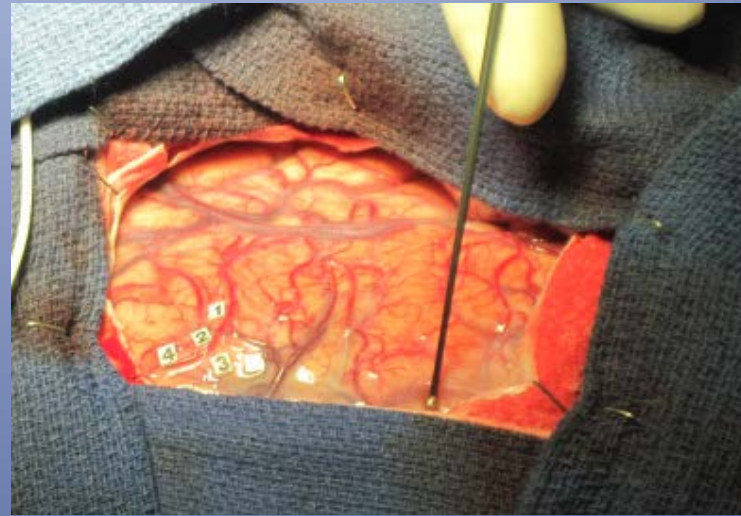
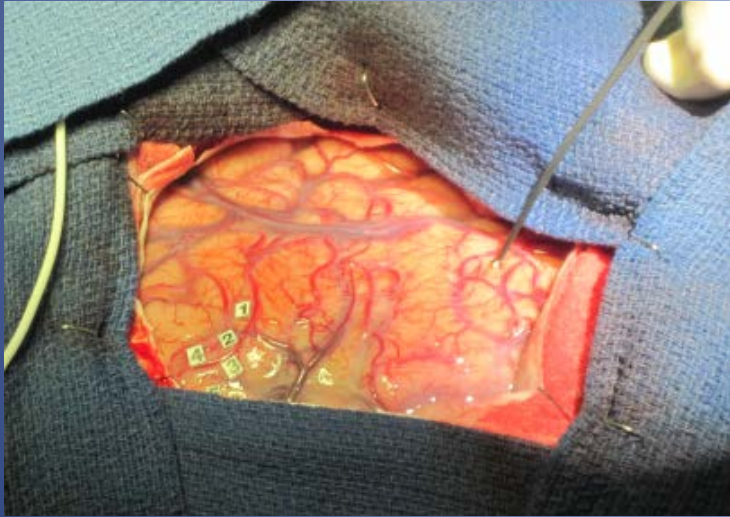
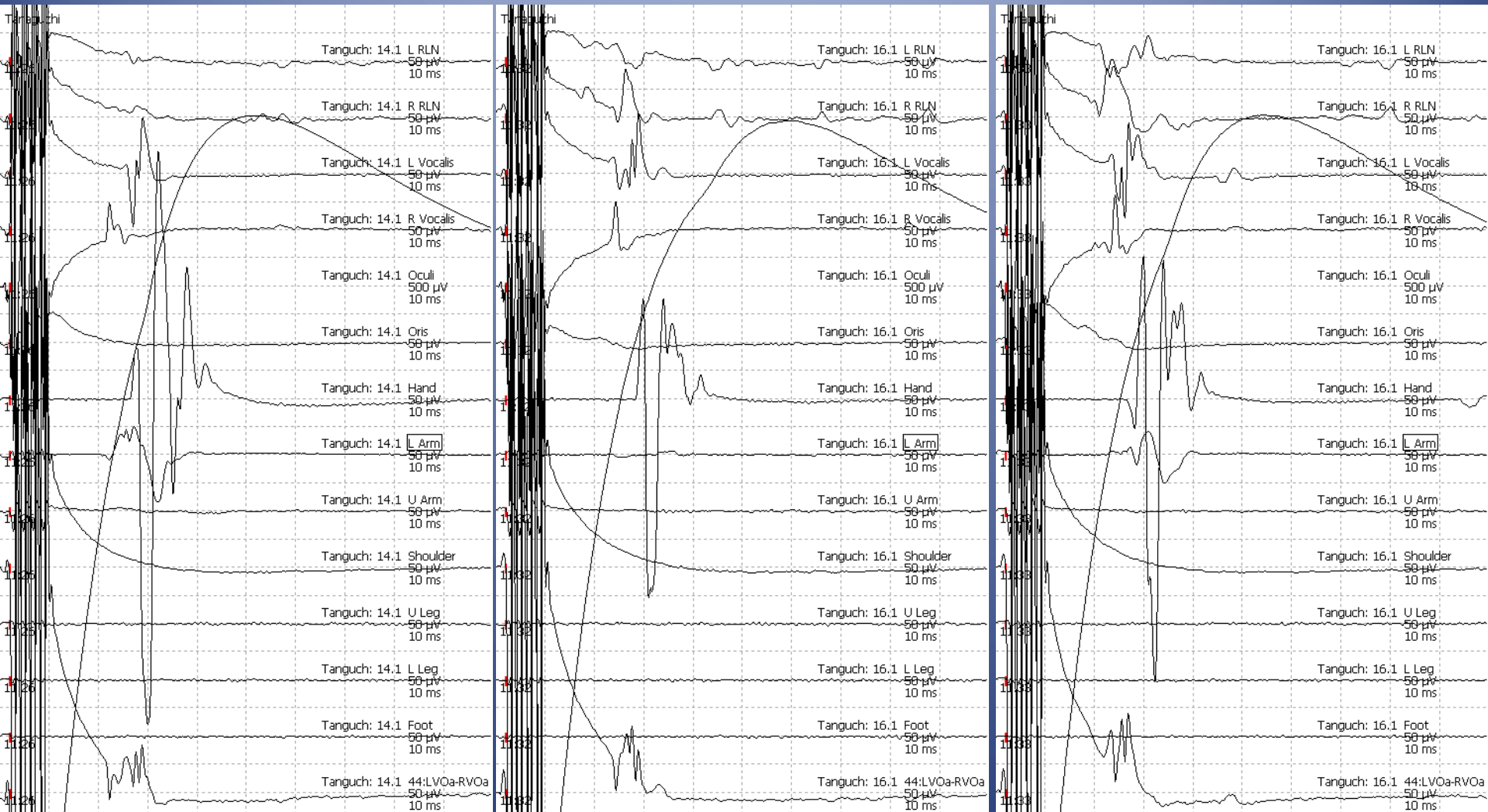




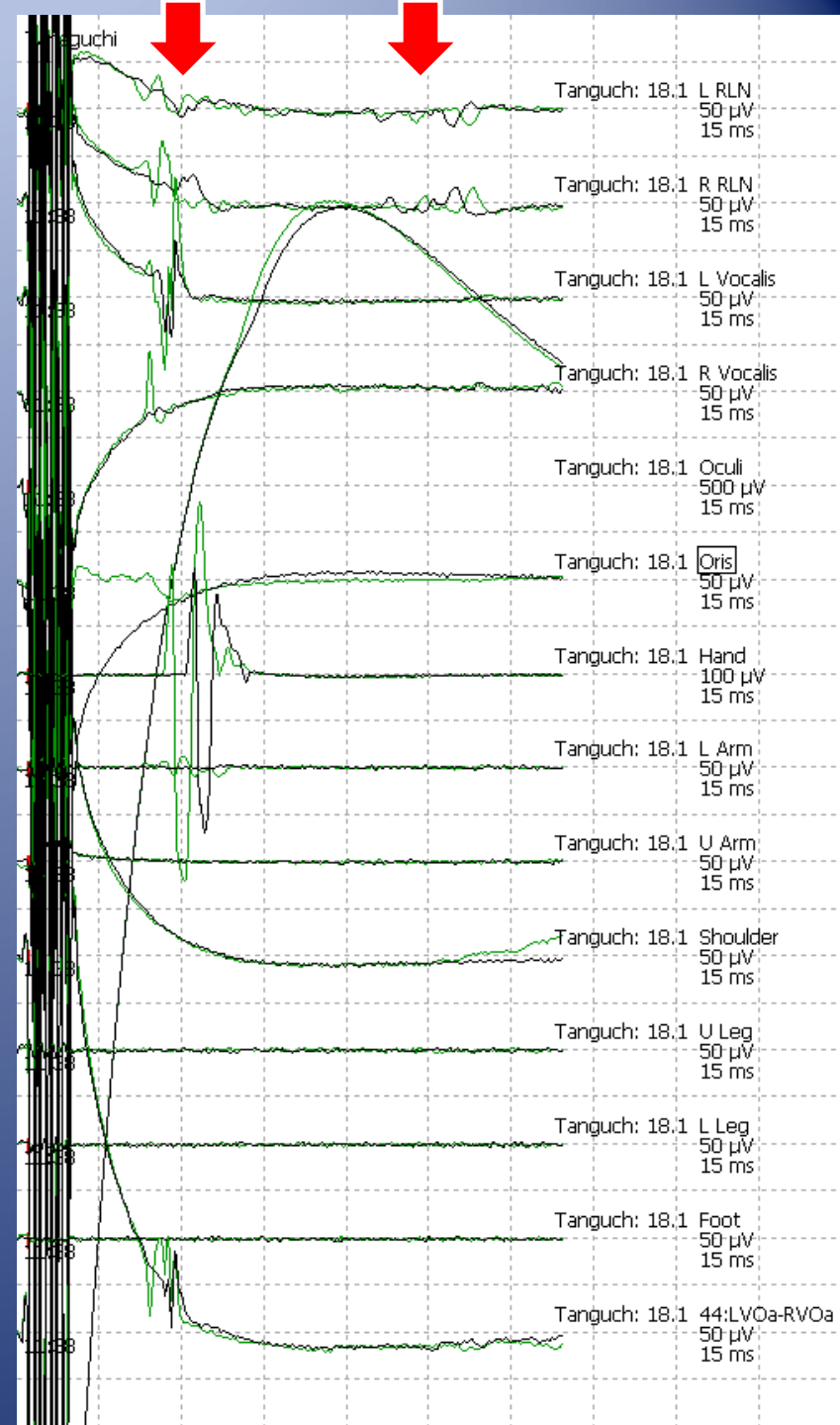
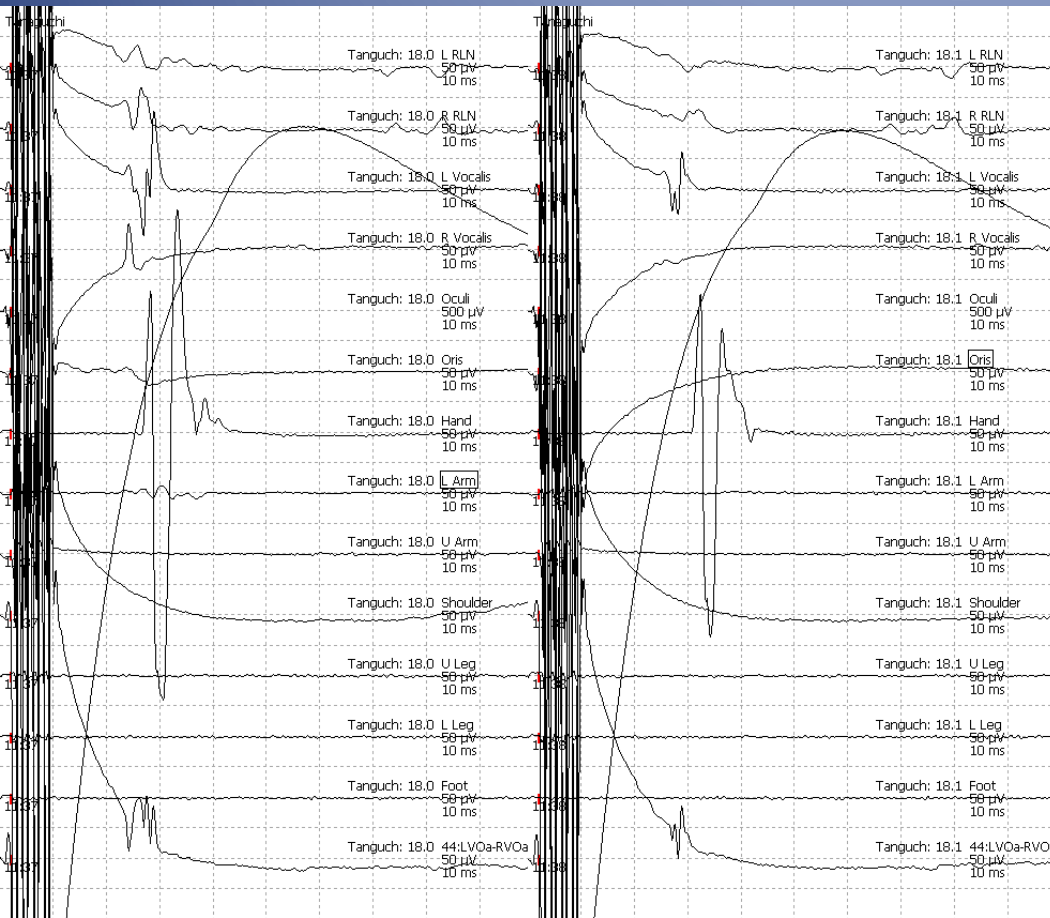
Mapping continued



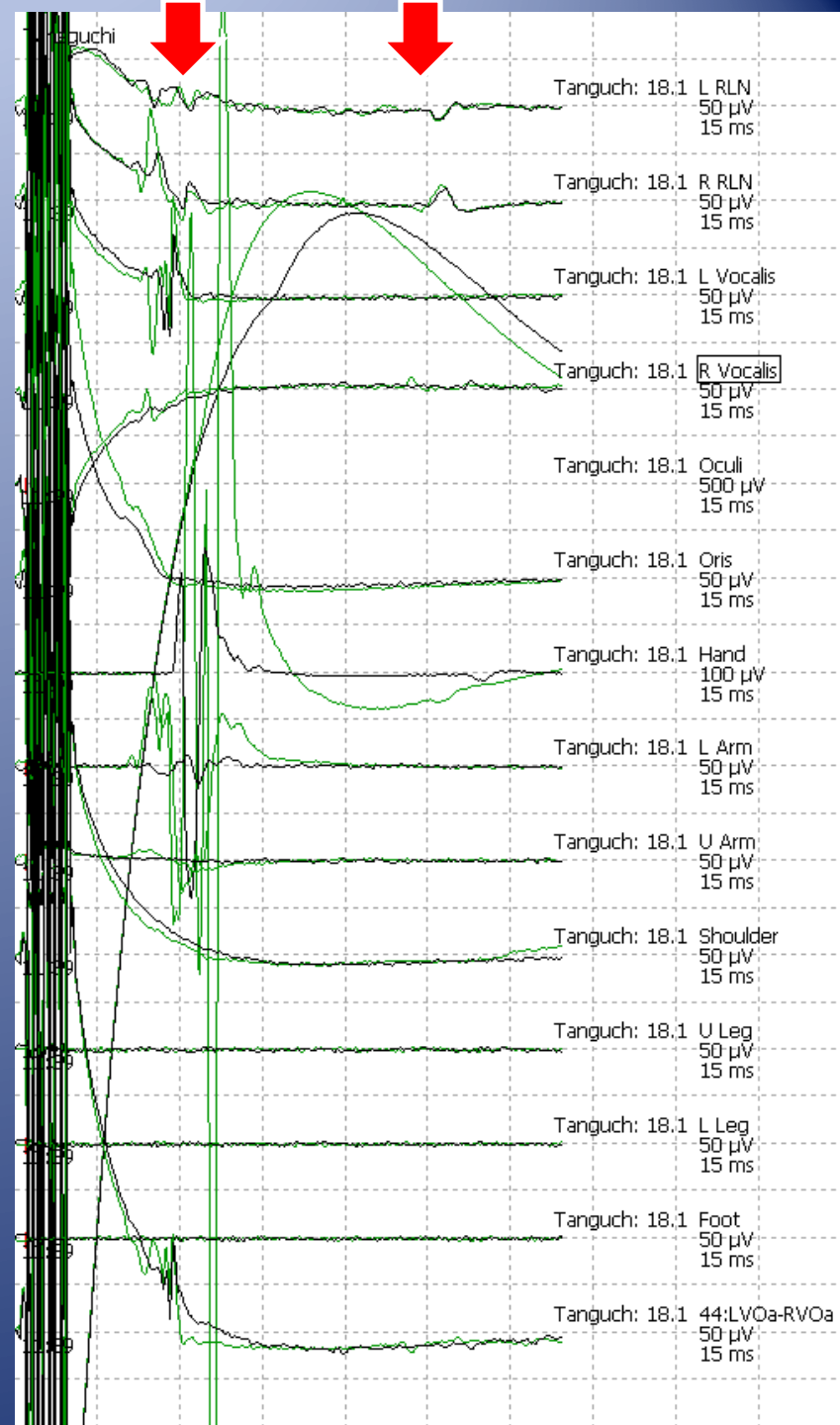
Short latency Vocalis and Hand

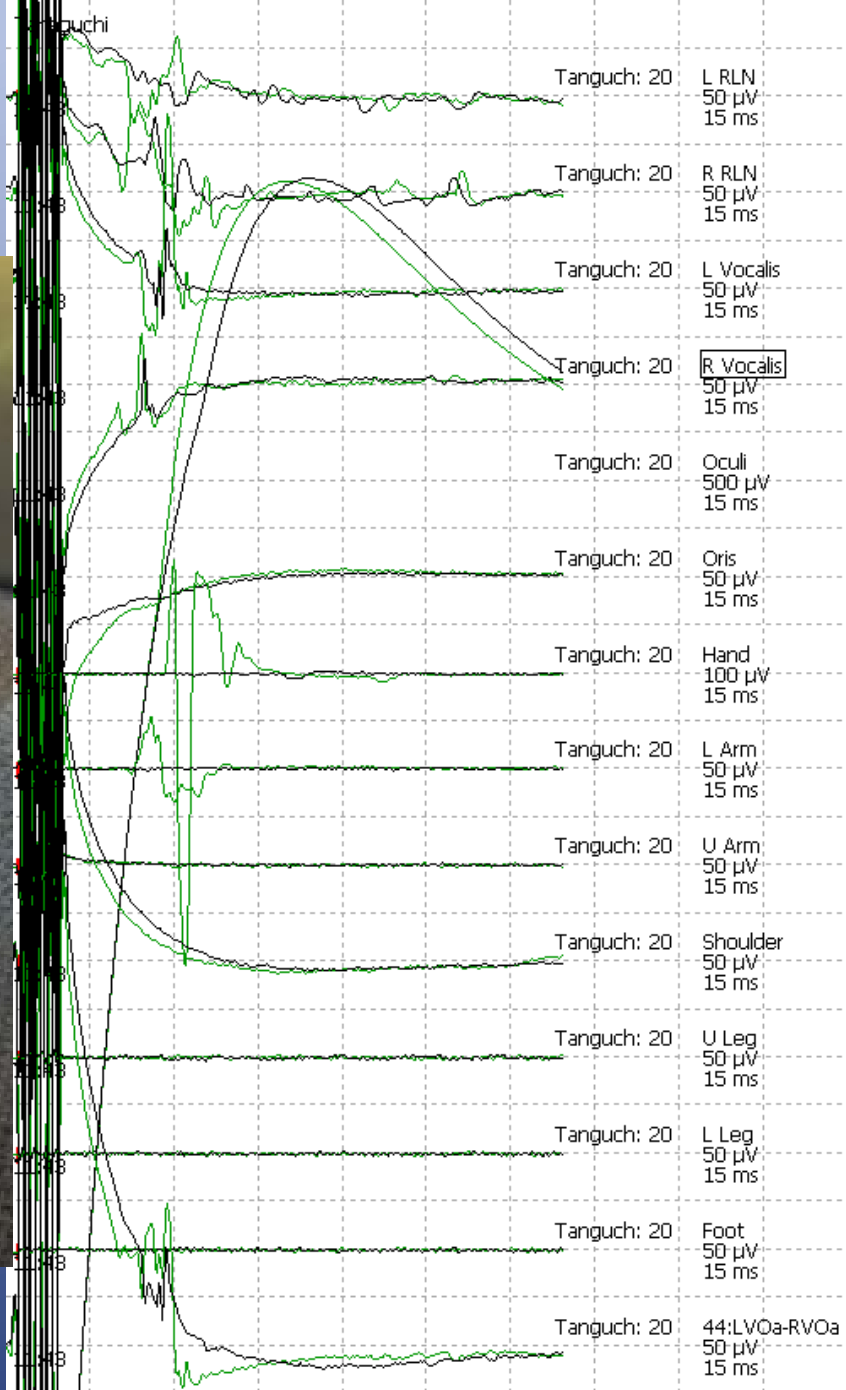
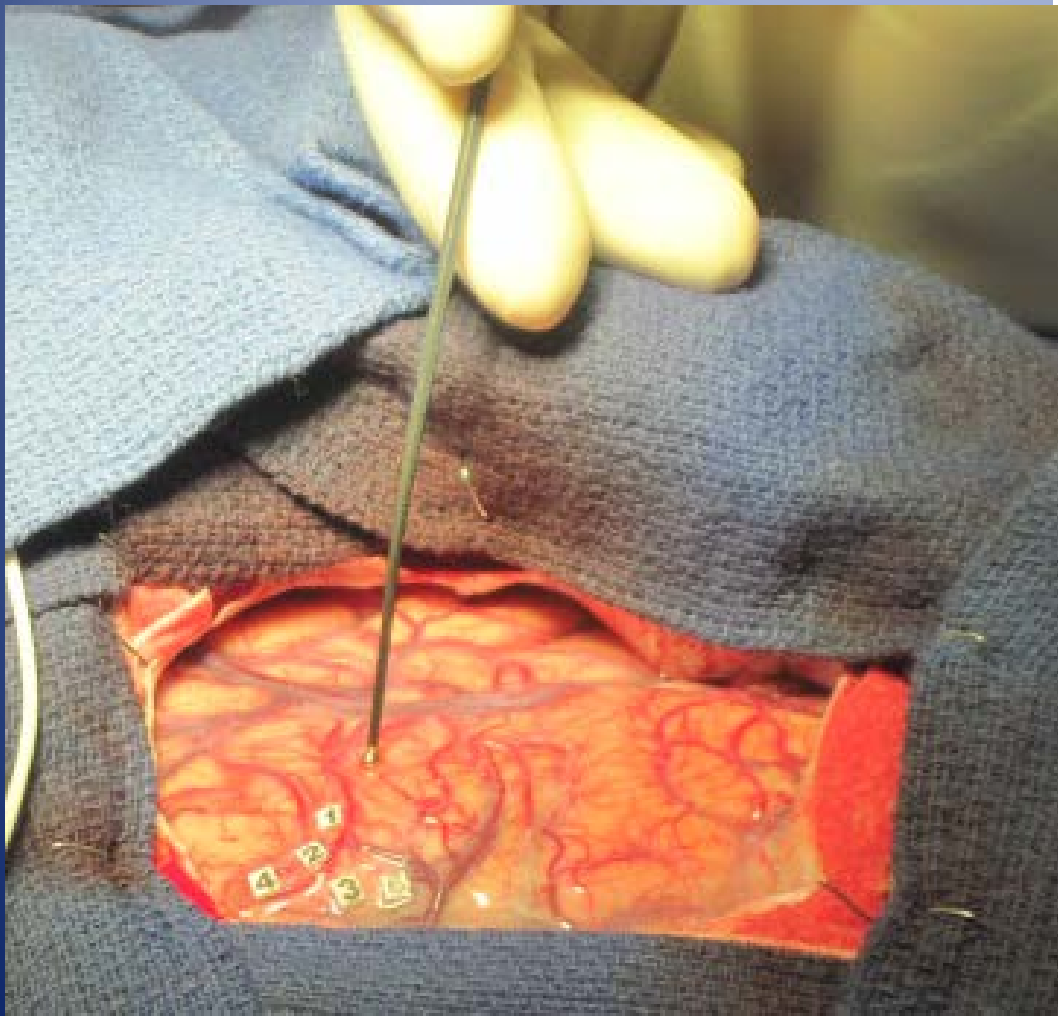



Short and possible long latency response





Despite the apparent repeatability of these long latency responses, there was continuous low amplitude random spike activity. See the stacked triggered data.



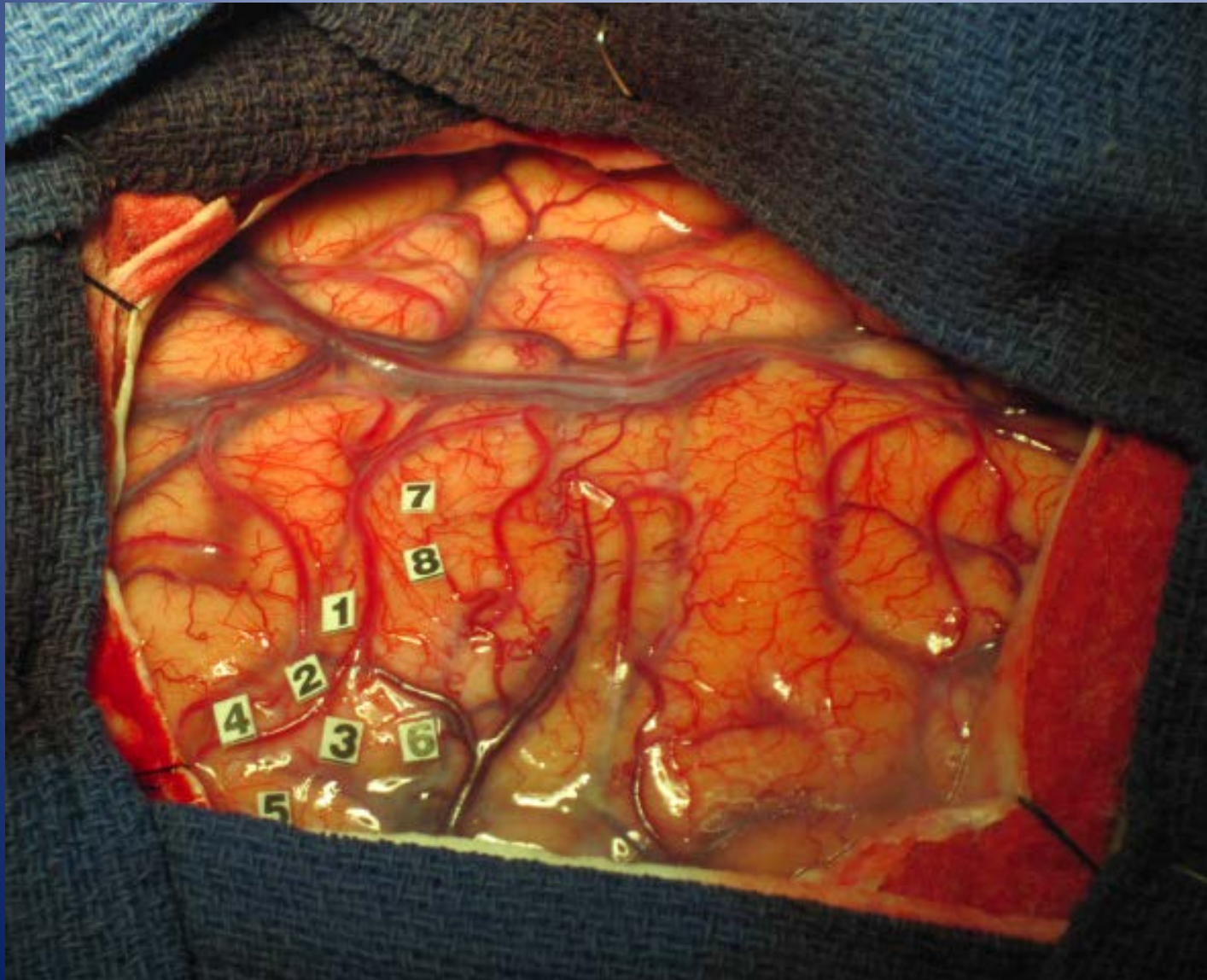








Final Mapping Results

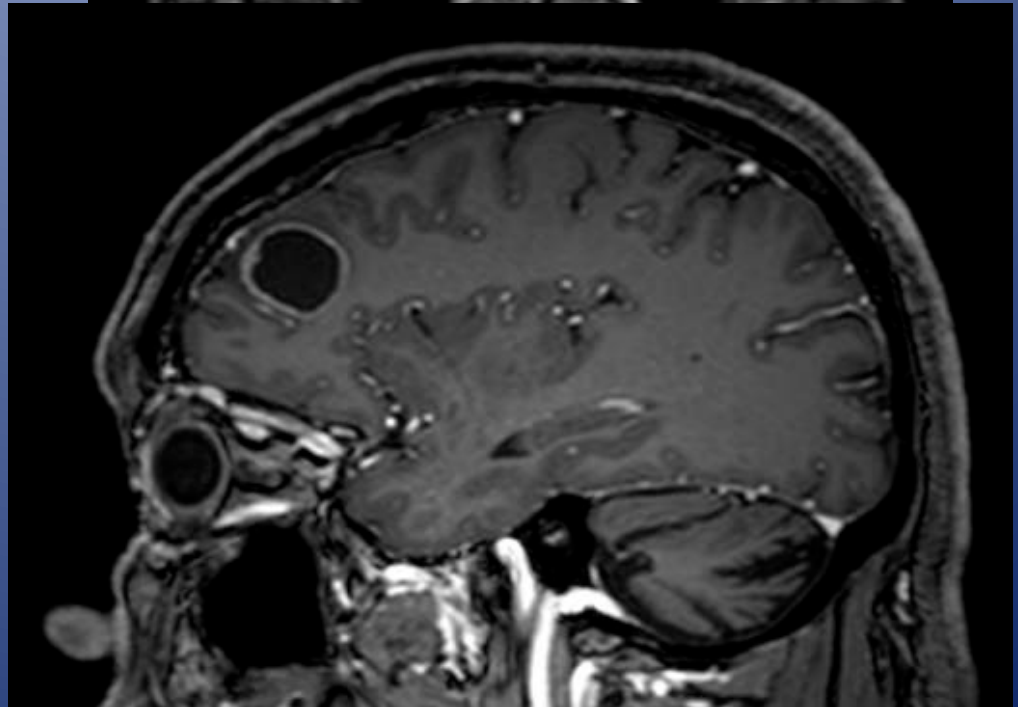
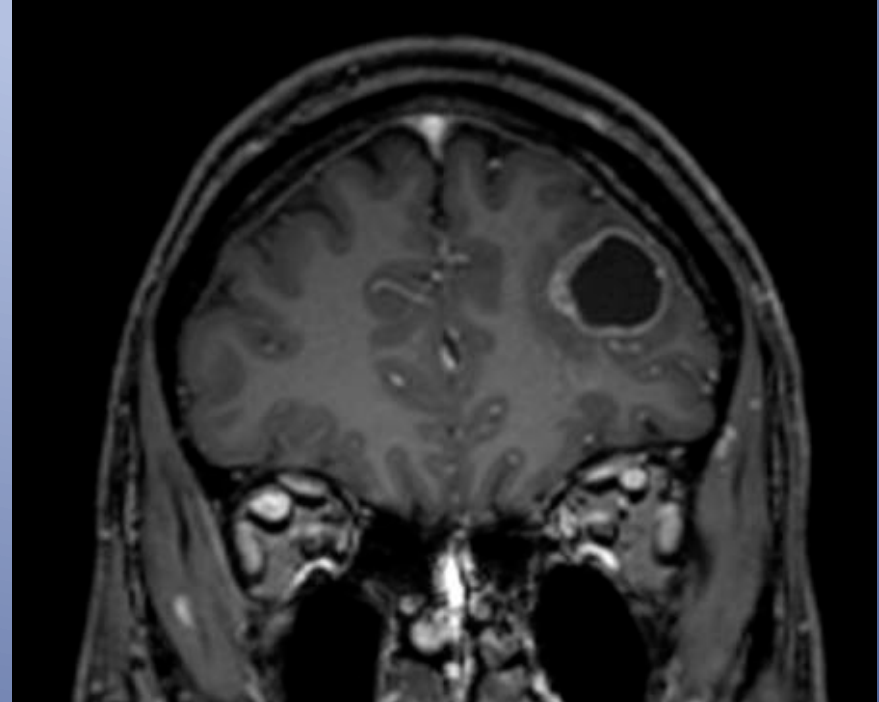
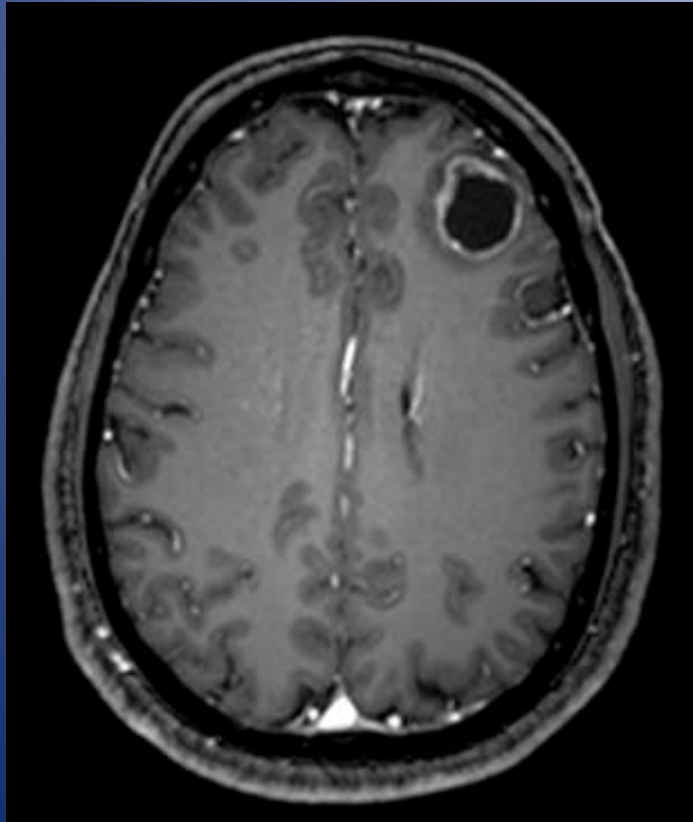


- 1 = SLR, hand, LA
- 2 = SLR, hand
- 3 = SLR, hand, LA
- 4 = SLR, hand
- 5 = hand
- 6 = SLR, hand
- 7 = SLR
- 8 = SLR, hand

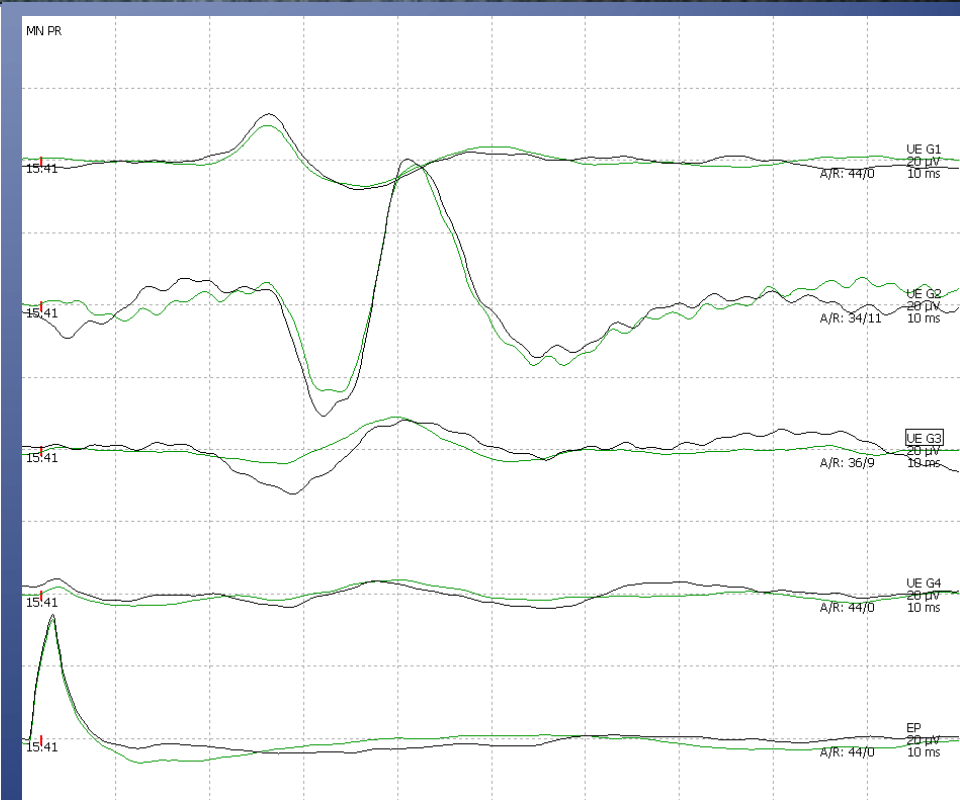
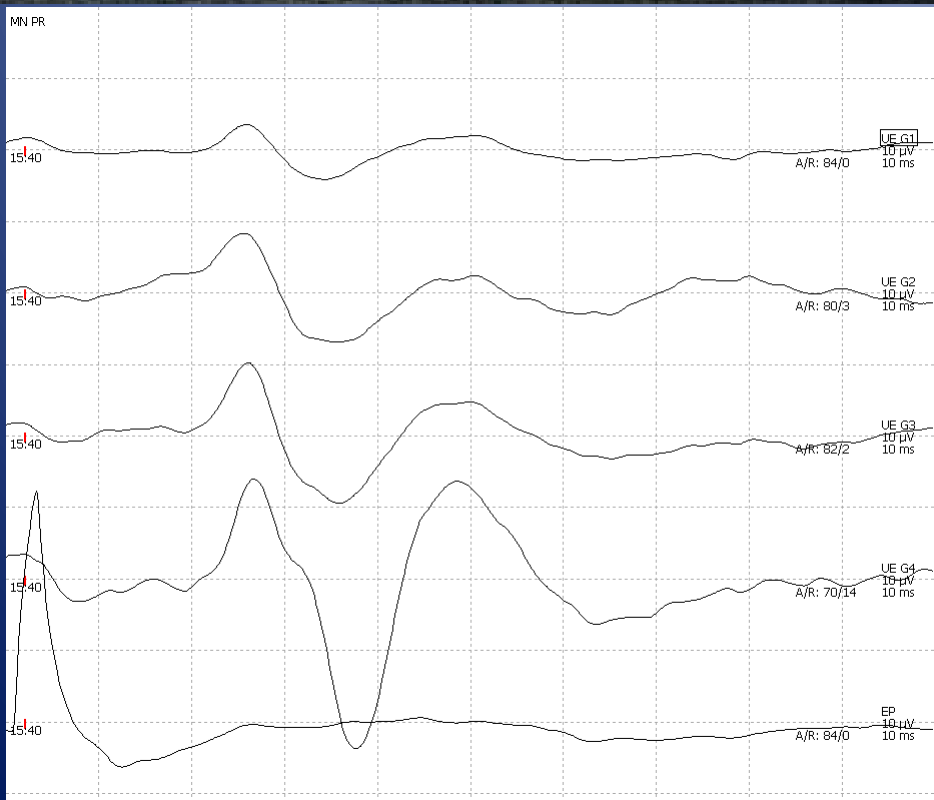
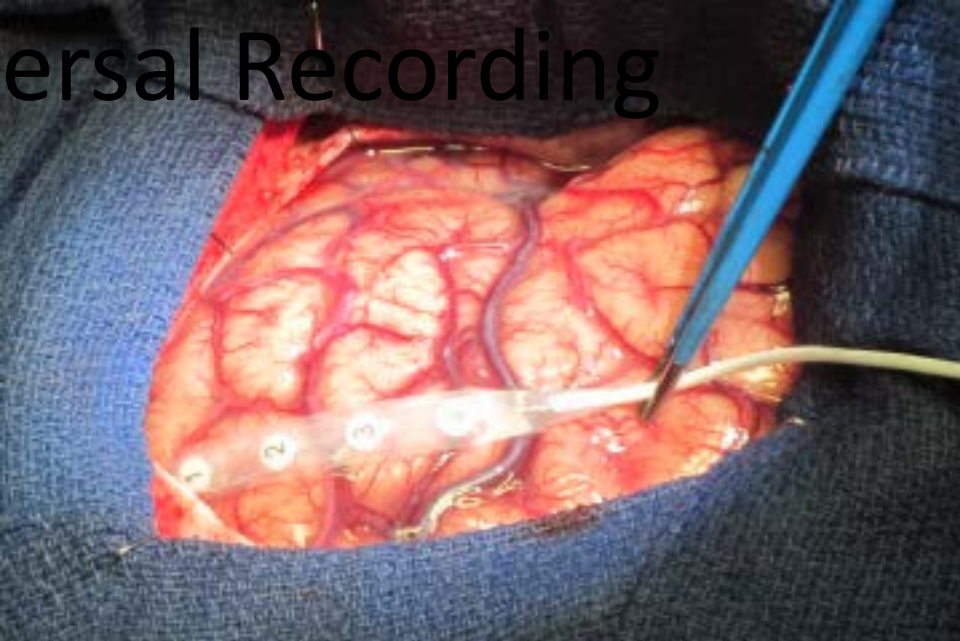
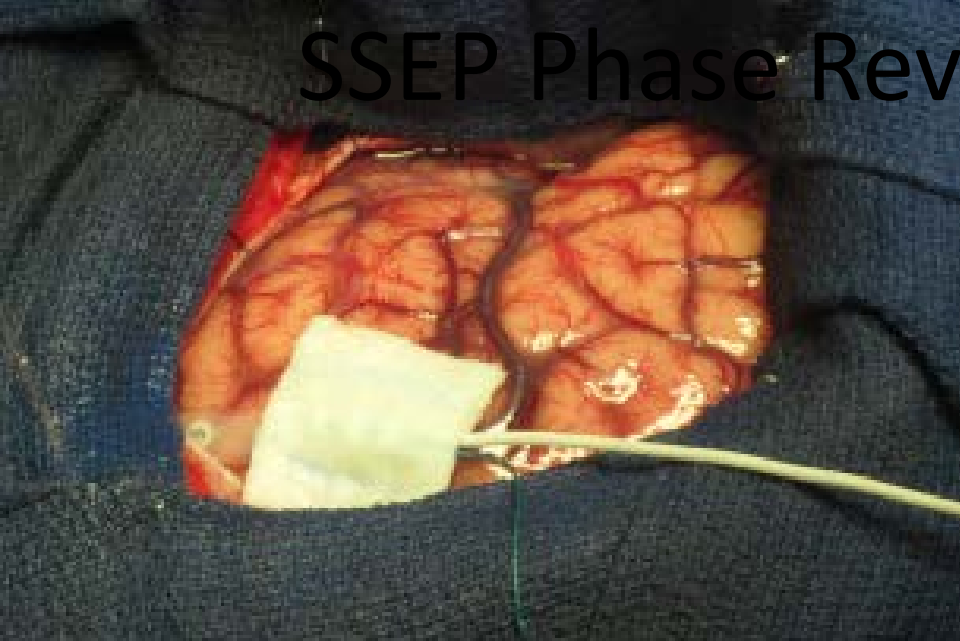Patient 4

- 58 y.o. male
- Diagnosis: **LEFT frontal** tumor (likely metastasis from primary salivary gland adenocarcinoma)
- Procedure: Stereotactic **LEFT frontal** craniotomy for volumetric resection of tumor

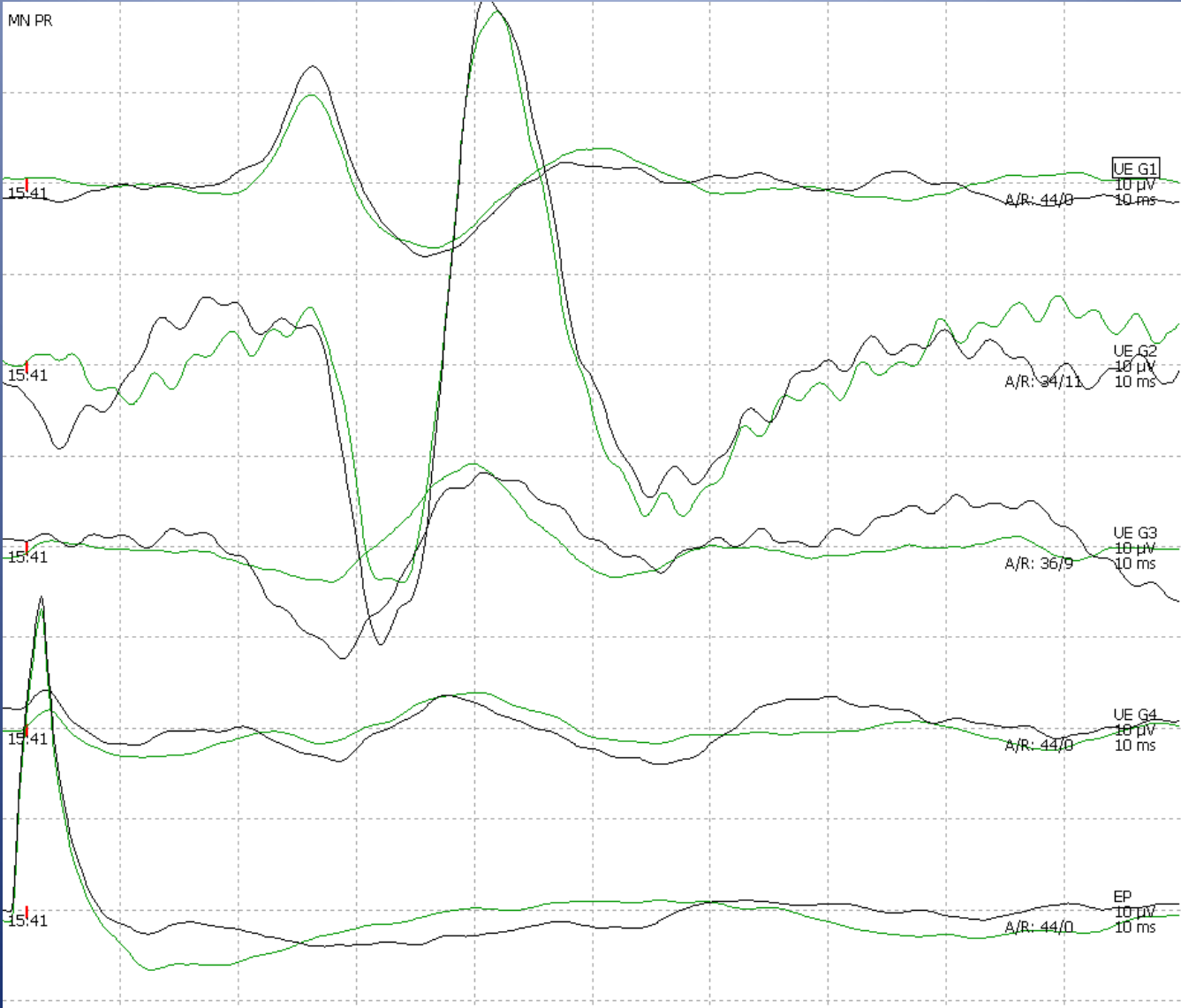
Images



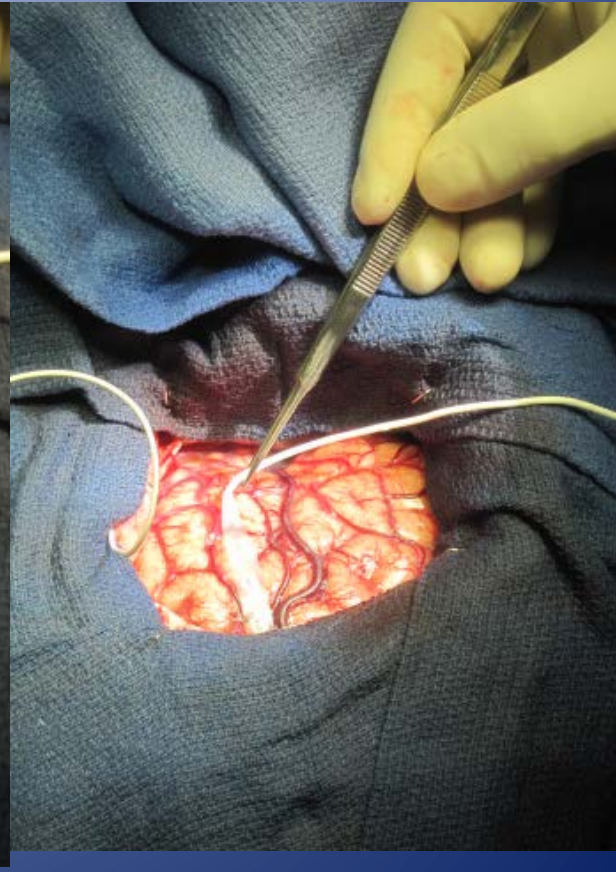
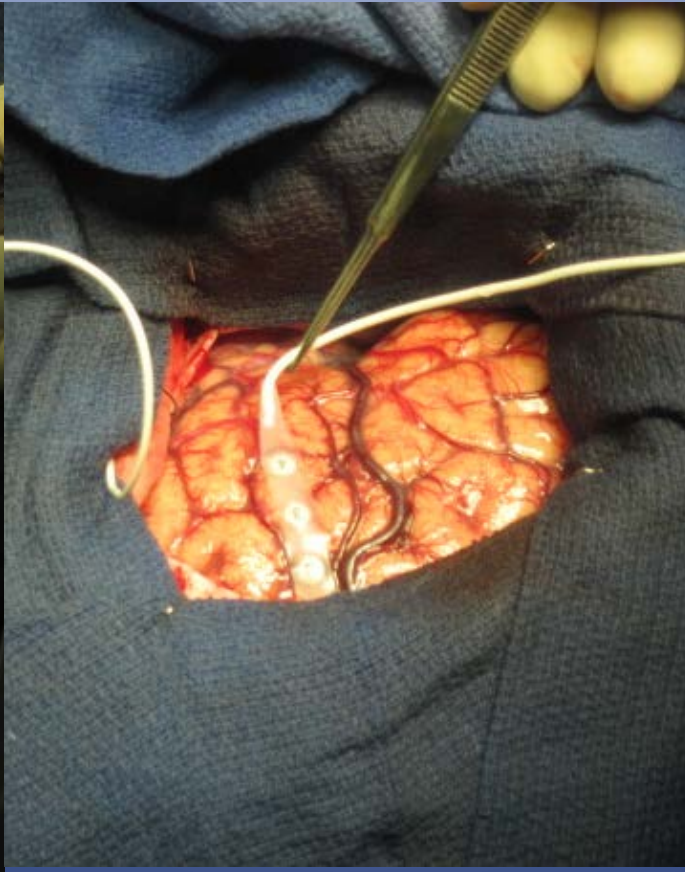
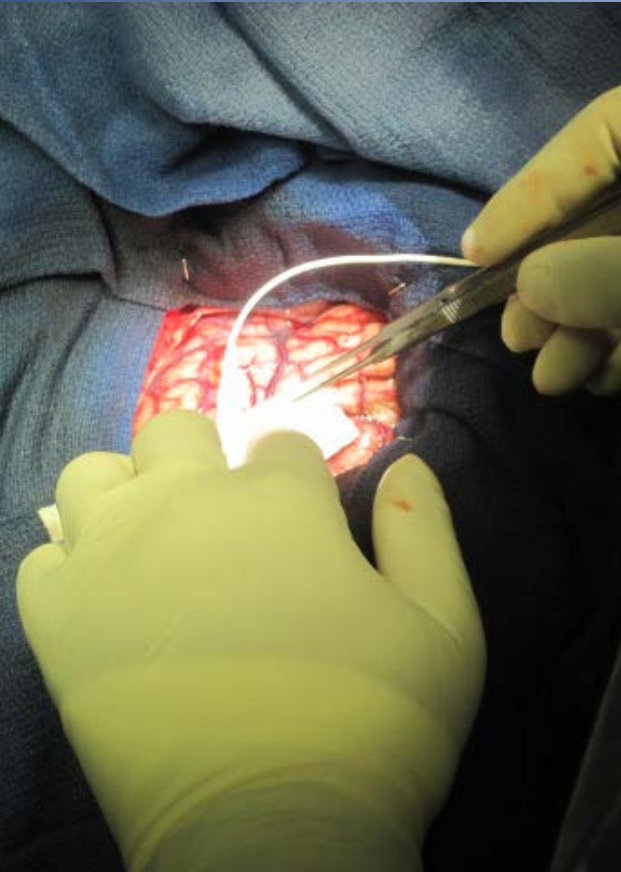
SSEP Phase Reversal Recording



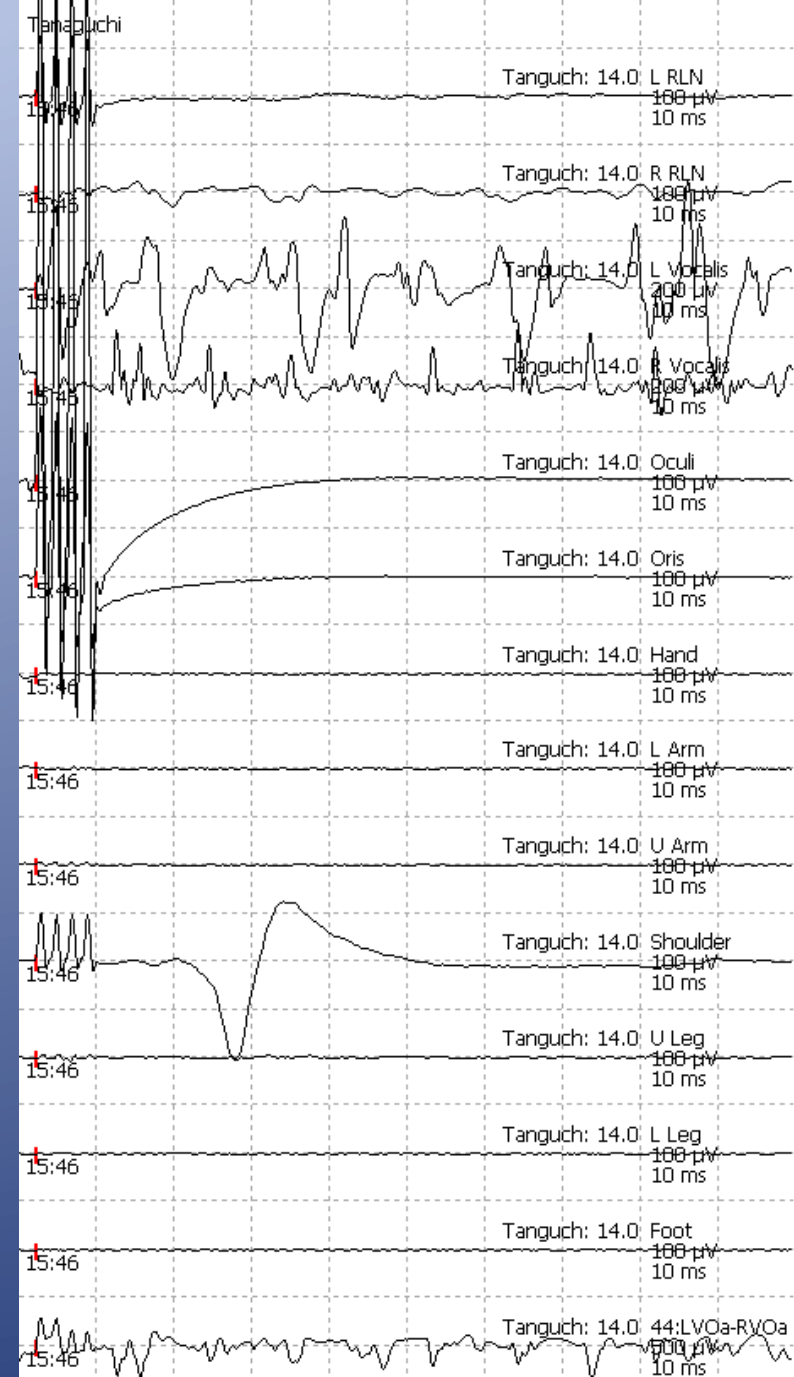
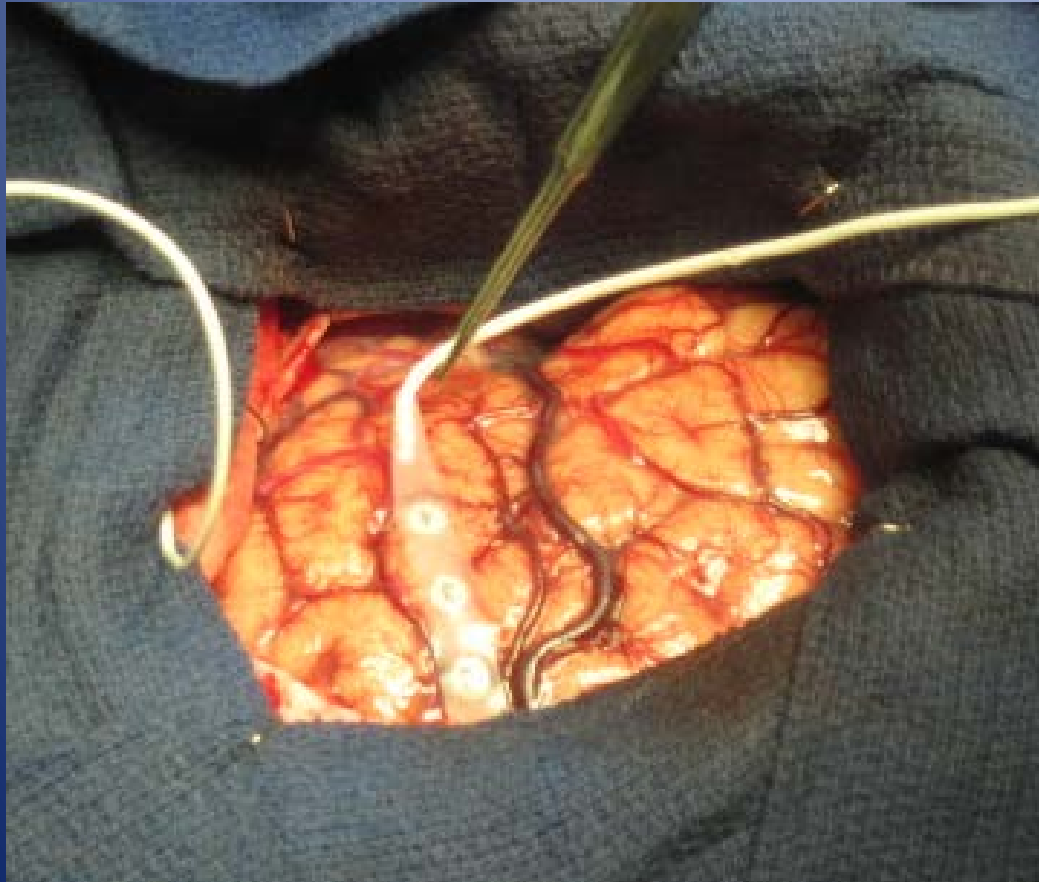
MN SSEP Phase Reversal Replication



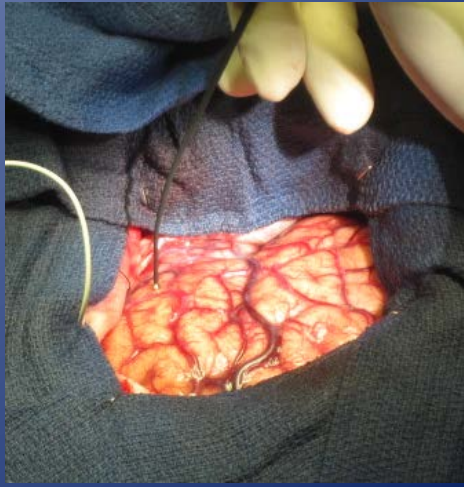
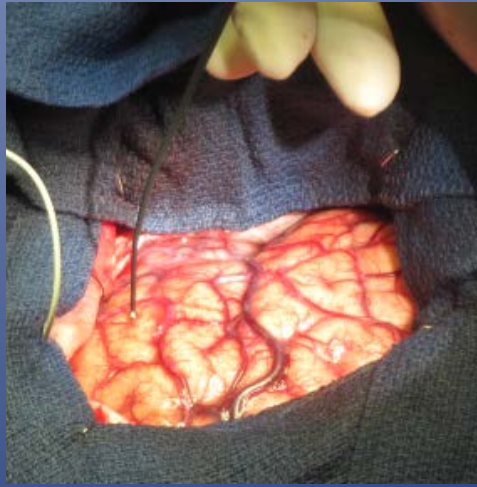
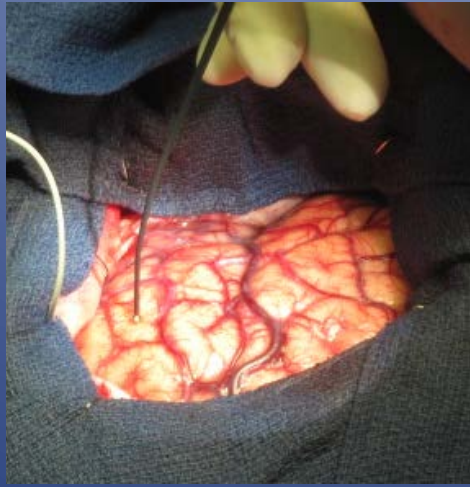
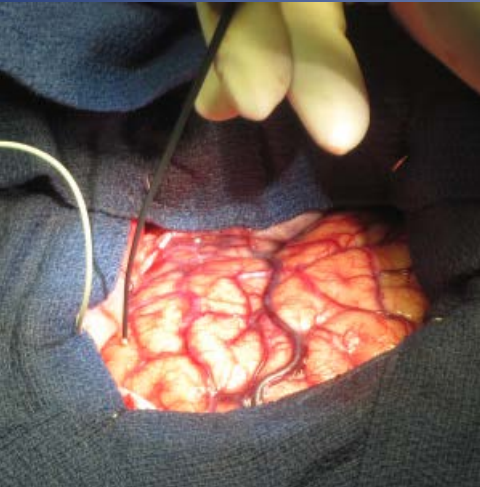
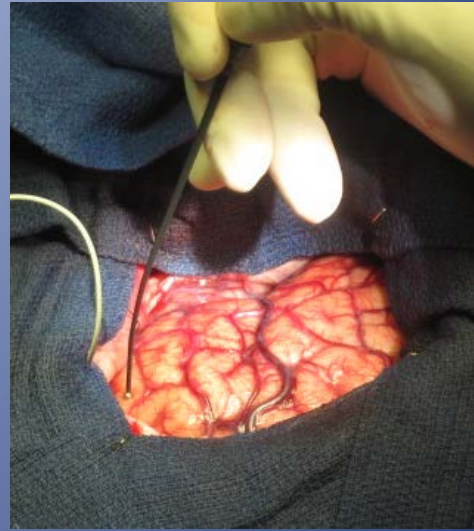
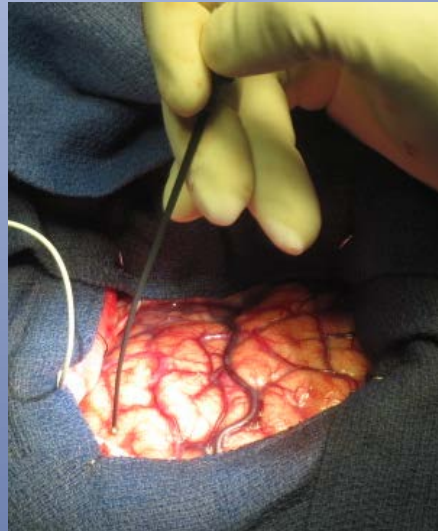
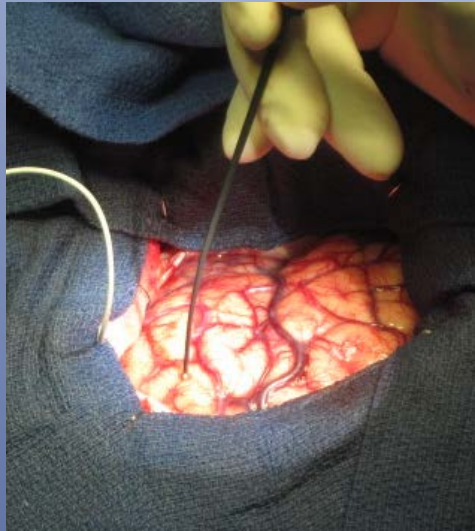
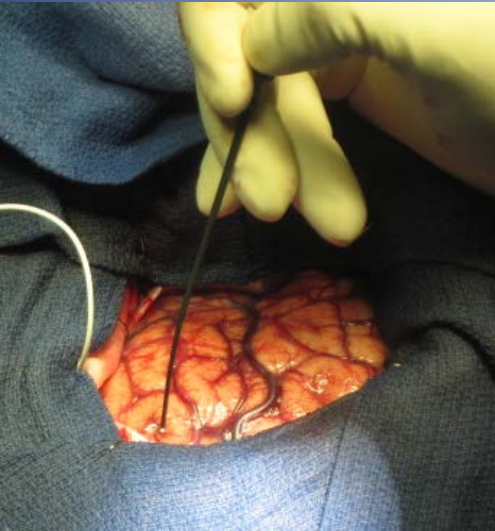Grid placed along the pre-central gyrus
to stimulate for motor responses

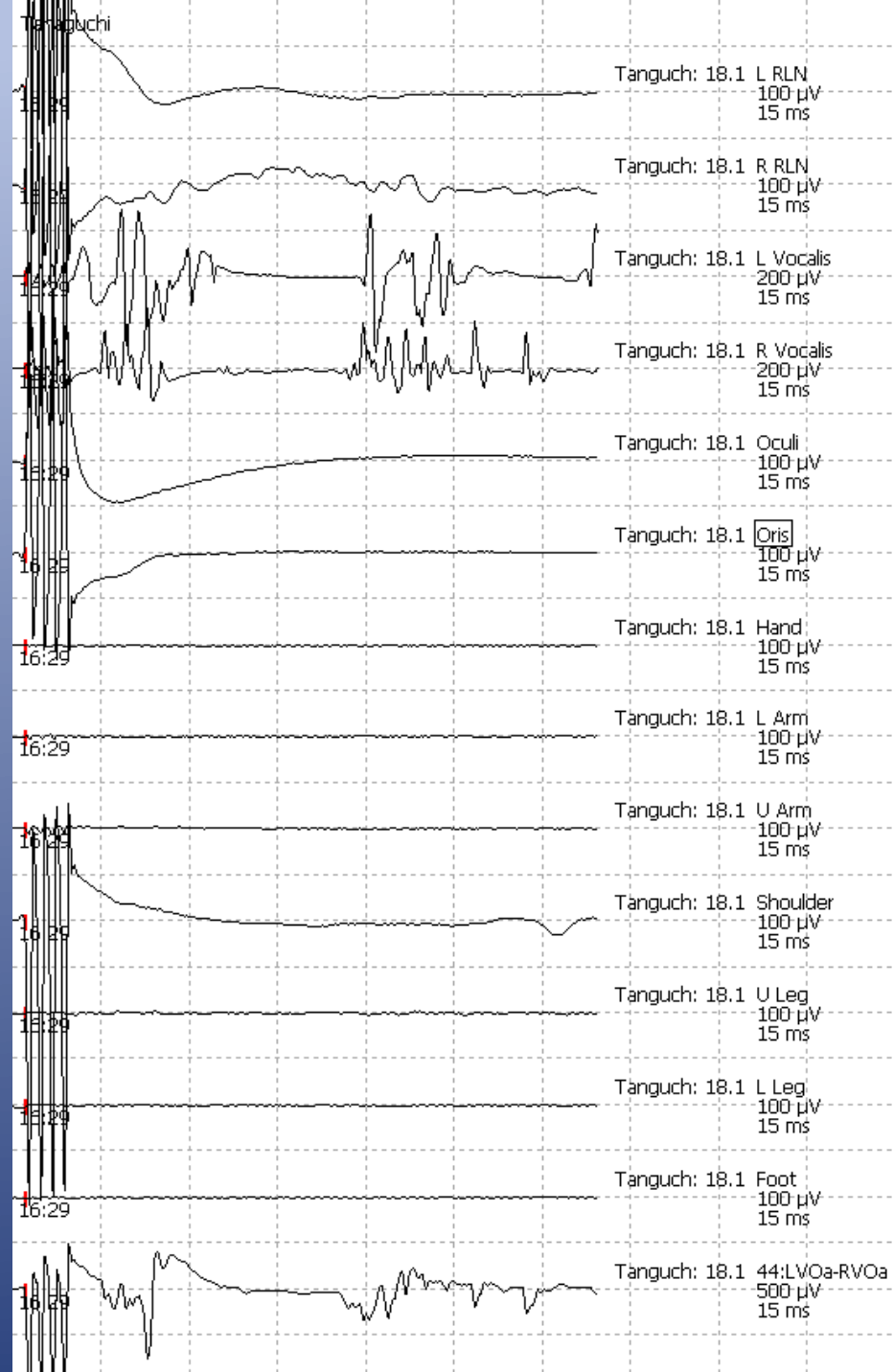
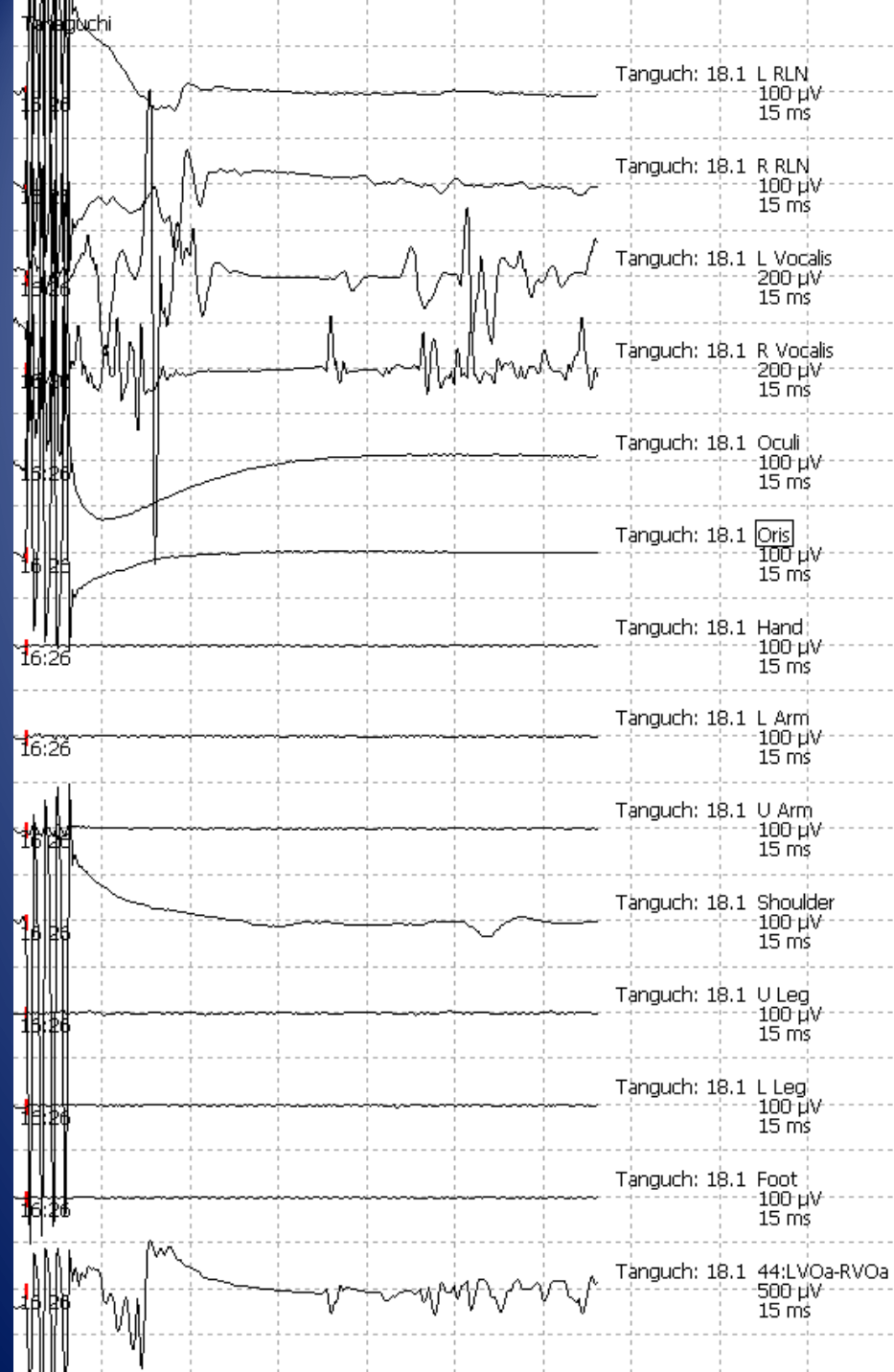


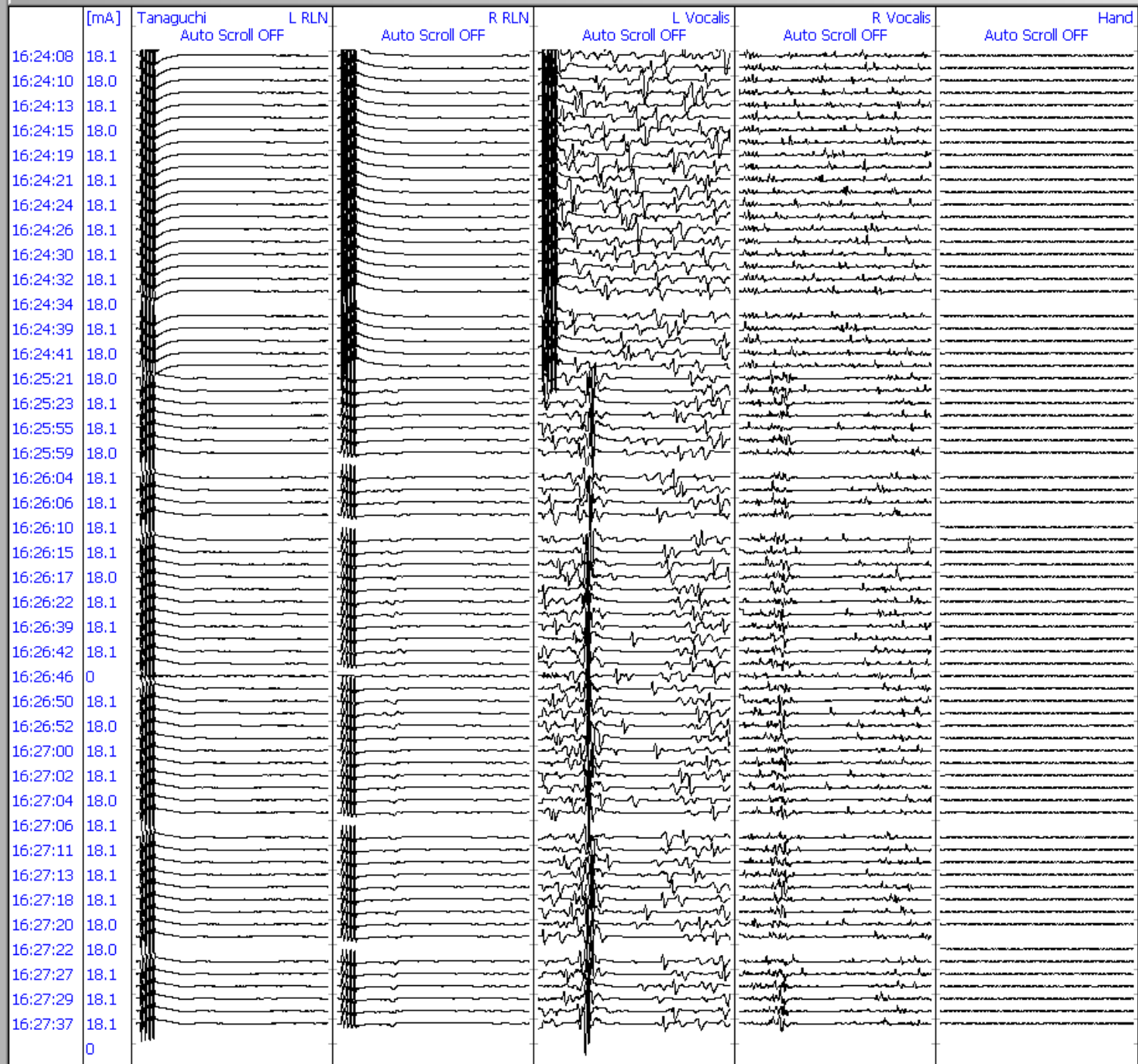
Grid stim 1-4, 14 mA



Systematic Stimulus Mapping Starting at 4 mA





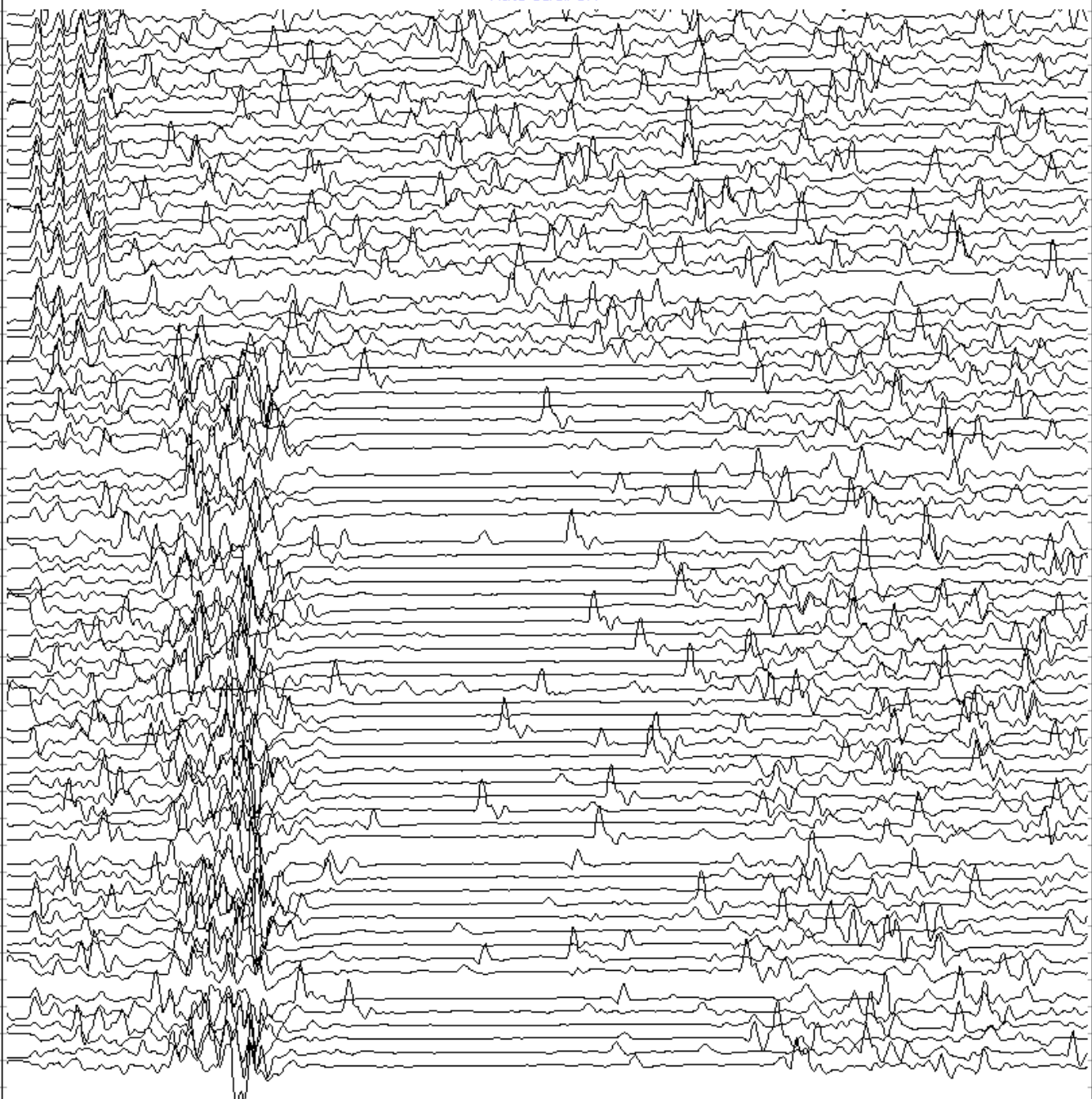


[mA]

ZOOM TRACE

Auto Scroll OFF

16:24:08 18.1
16:24:10 18.0
16:24:13 18.1
16:24:15 18.0
16:24:19 18.1
16:24:21 18.1
16:24:24 18.1
16:24:26 18.1
16:24:30 18.1
16:24:32 18.1
16:24:34 18.0
16:24:39 18.1
16:24:41 18.0
16:25:21 18.0
16:25:23 18.1
16:25:55 18.1
16:25:59 18.0
16:26:04 18.1
16:26:06 18.1
16:26:10 18.1
16:26:15 18.1
16:26:17 18.0
16:26:22 18.1
16:26:39 18.1
16:26:42 18.1
16:26:46 0
16:26:50 18.1
16:26:52 18.0
16:27:00 18.1
16:27:02 18.1
16:27:04 18.0
16:27:06 18.1
16:27:11 18.1
16:27:13 18.1
16:27:18 18.1
16:27:20 18.0
16:27:22 18.0
16:27:27 18.1
16:27:29 18.1
16:27:37 18.1
0

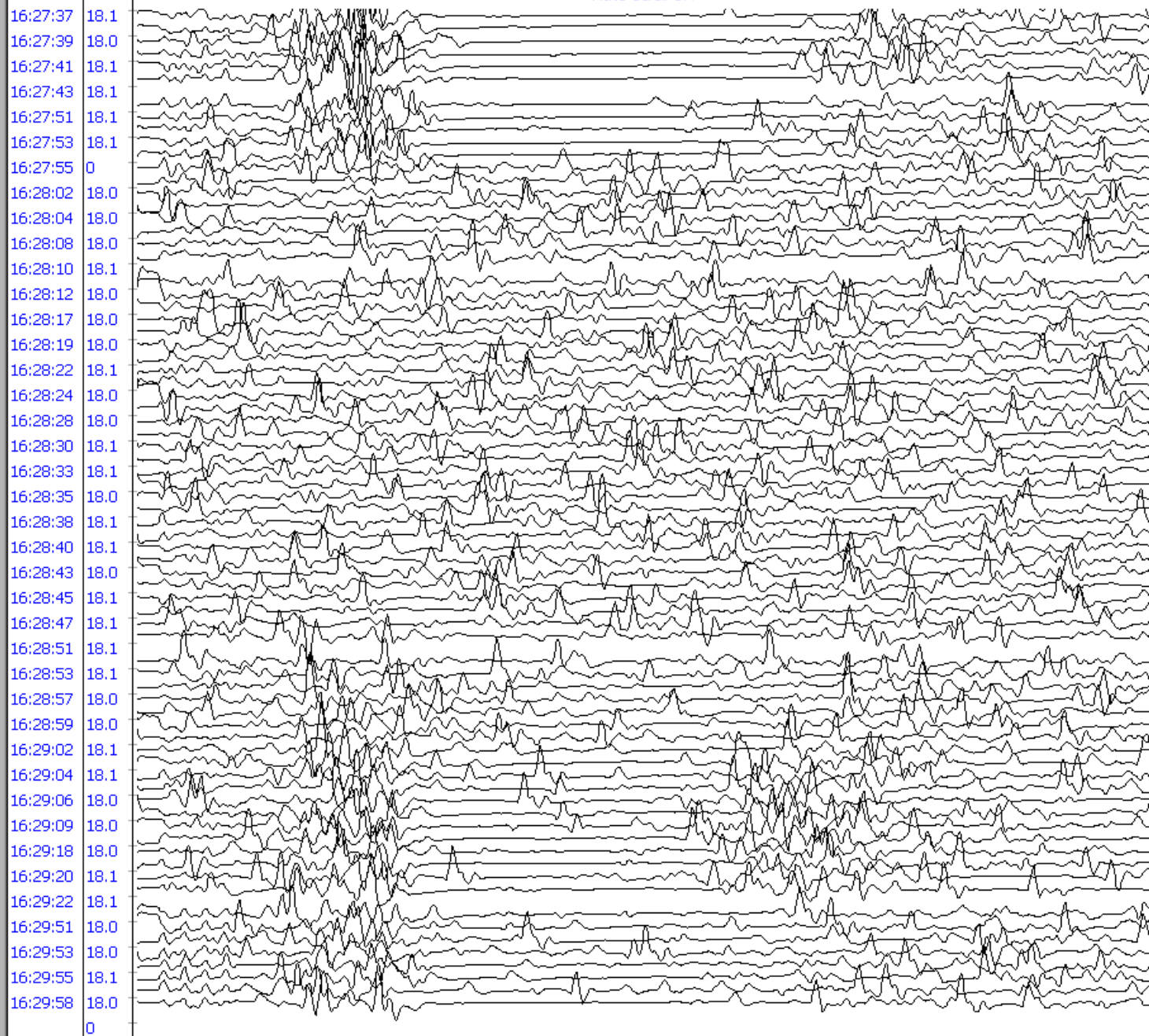


[mA]

ZOOM TRACE

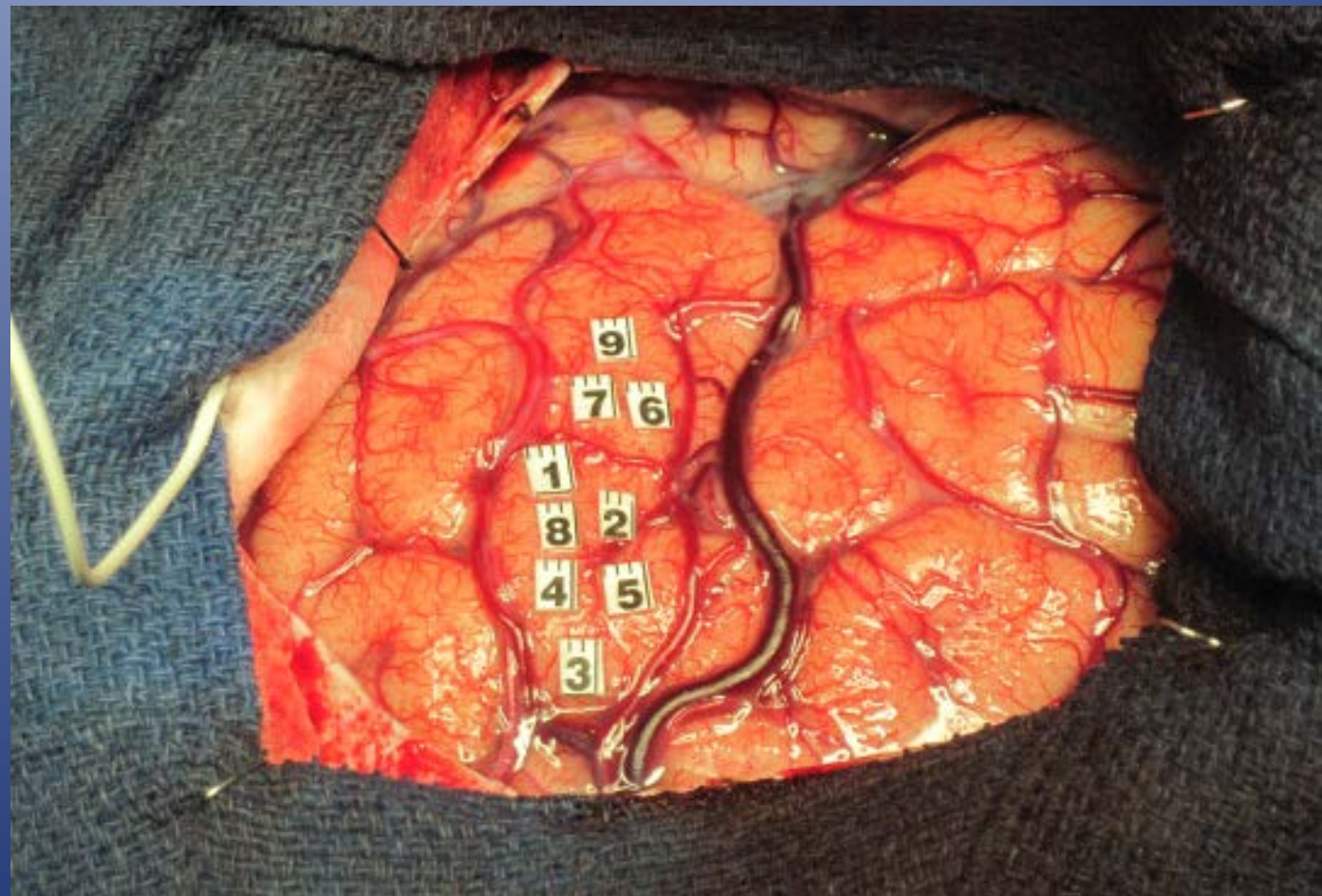
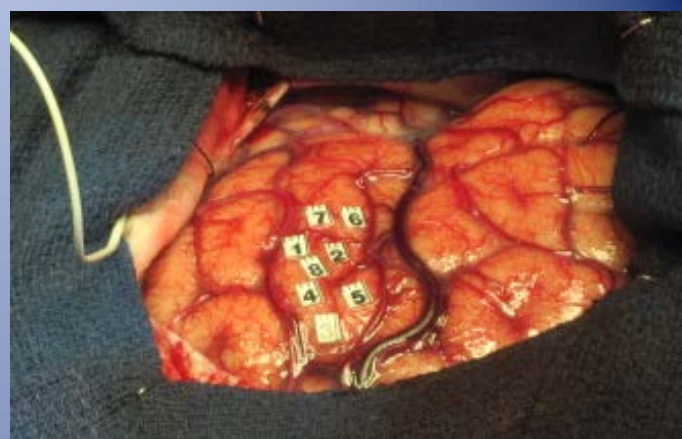
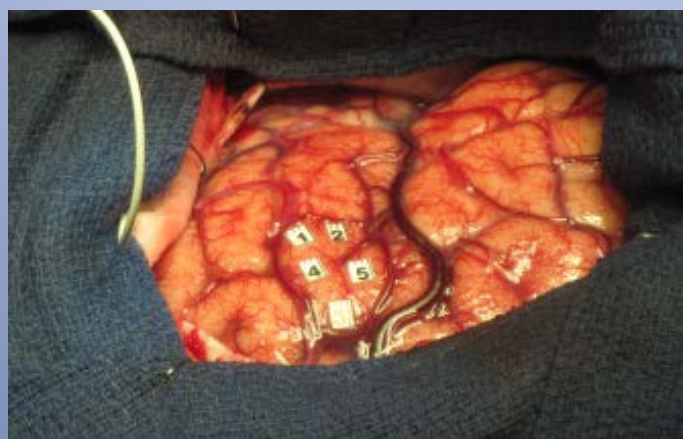
Auto Scroll OFF

R. Vocalis



Sterile Labels Placed Where Motor Responses Obtained

Short latency vocalis responses obtained at all numbered sites. Long latency responses also observed at 8,2,7 and 9



Discussion

- Only the hookwires picked up responses in this case; it is clear that both ET tube and hookwires are necessary.
- Clearer responses were recorded by ipsilateral vocalis in this case;
- This patient had continuous random activity coming from the vocalis recordings making it challenging to see the evoked responses; especially the LLR which were low amplitude.

Summary

- Clear long latency compound muscle action potentials were recorded in 3 of 4 patients.
 - Long latency CMAPs were likely recorded in the 4th patient, but the presence of spontaneous EMG activity made interpretation difficult.
- Based on our findings this technique appears to be an effective method for mapping broca's area in patients that are not candidates for standard language mapping.

Tips

- Both hookwire and endotracheal tube recording electrodes must be placed
- To isolate the long latency response and avoid current spread, careful titration of monopolar stimulation is necessary
- Bilateral recordings must be performed
- Cathode location is important
 - Frontal cathode produces significant stim artifact on the oculi channel
 - Lateral temporalis cathode was used and appeared to work well, however MEPs were generally low amplitude
 - Ipsilateral mastoid cathode did NOT produce responses where we were reproducibly getting them using the temporalis cathode

Tips

- Paired hookwires were more easily placed than single hookwires (too many wires to deal with during placement). The singles also fell out of their needle too easily.

THANK YOU!